

## Acta Cirúrgica Brasileira



All the contents of this journal, except where otherwise noted, is licensed under a Creative Commons Attribution License. Fonte:

[https://www.scielo.br/scielo.php?script=sci\\_arttext&pid=S0102-86502013000700003&lng=en&tlng=en](https://www.scielo.br/scielo.php?script=sci_arttext&pid=S0102-86502013000700003&lng=en&tlng=en). Acesso em: 04 dez. 2020.

### REFERÊNCIA

FREITAS, Pedro Felipe Silva de *et al.* Effects of pneumoperitoneum with carbon dioxide and helium on renal function and morphology in rats. **Acta Cirúrgica Brasileira**, São Paulo, v. 28, n. 7, p. 494-498, jul. 2013. DOI: <http://dx.doi.org/10.1590/S0102-86502013000700003>. Disponível: [http://www.scielo.br/scielo.php?script=sci\\_arttext&pid=S0102-86502013000700003&lng=en&nrm=iso](http://www.scielo.br/scielo.php?script=sci_arttext&pid=S0102-86502013000700003&lng=en&nrm=iso). Acesso em: 04 dez. 2020.

## Effects of pneumoperitoneum with carbon dioxide and helium on renal function and morphology in rats<sup>1</sup>

Pedro Felipe Silva de Freitas<sup>I</sup>, Leonardo Castro Durães<sup>II</sup>, Felipe Augusto Neves Oliveira de Carvalho<sup>III</sup>, Sérgio Andurte Carvalho Duarte<sup>III</sup>, Fabiana Pirani Carneiro<sup>IV</sup>, João Batista de Sousa<sup>V</sup>

<sup>I</sup>Graduate student, School of Medicine, UnB, Brasilia-DF, Brazil. Acquisition and interpretation of data, technical procedures, statistical analysis, manuscript writing.

<sup>II</sup>Fellow Master degree, Postgraduate Program in Medical Sciences, School of Medicine, UnB, Brasilia-DF, Brazil. Technical procedures, statistical analysis, interpretation of data, critical revision.

<sup>III</sup>Graduate student, School of Medicine, UnB, Brasilia-DF, Brazil. Acquisition and interpretation of data, technical procedures, critical revision.

<sup>IV</sup>PhD, Associate Professor of Pathology, School of Medicine, UnB, Brasilia-DF, Brazil. Macroscopic and histopathological examinations, interpretation of data, critical revision.

<sup>V</sup>PhD, Associate Professor of Surgery, School of Medicine, UnB, Brasilia-DF, Brazil. Intellectual, scientific content and design of the study; technical procedures; interpretation of data; manuscript writing; critical revision.

---

### ABSTRACT

**PURPOSE:** To evaluate the effects of pneumoperitoneum with carbon dioxide and helium on renal function and morphology in a rat model.

**METHODS:** Twenty four rats were randomized into three groups (n=8): gasless insufflation ('open', Pressure=0 mmHg), carbon dioxide pneumoperitoneum at 12 mmHg, and helium pneumoperitoneum at 12 mmHg; all lasting 90 minutes.. A cystostomy was performed and the bladder was emptied. At the end of the experiment, the urine produced, a blood sample and the left kidney of each animal were collected. The following variables were obtained: serum sodium, potassium, urea and creatinine, urine volume and creatinine. The creatinine clearance was estimated for each animal. The kidneys were stained with hematoxylin and eosin (HE) and evaluated by a pathologist blinded to the groups.

**RESULTS:** The CO<sub>2</sub> and Helium groups did not differ in the variables evaluated. Both developed oliguria (p<0.001 vs. gasless). The CO<sub>2</sub> group presented hyperkalemia compared to gasless (p=0.05), which did not attain significance in the helium group. Histopathological analysis revealed mild hydropic degeneration and congestion in the three groups, with no significant difference among them.

**CONCLUSIONS:** The type of gas resulted in no difference in the variables of renal function and morphology assessed. The increase in serum potassium was only observed with CO<sub>2</sub> insufflation suggests a combined effect of elevated intra-abdominal pressure and metabolic effects of pneumoperitoneum.

**Key words:** Surgery. Laparoscopy. Pneumoperitoneum. Artificial. Carbon Dioxide. Helium. Kidney. Rats.

---

## Introduction

Pneumoperitoneum (PP) is essential for adequate exposure in laparoscopic surgery<sup>1</sup>. Laparoscopic access, in turn, is associated with decreased pain, lower morbidity, superior cosmesis, shorter postoperative stay and return to preoperative activities as compared with open techniques<sup>2-5</sup>. Carbon dioxide (CO<sub>2</sub>) is the gas employed most widely for insufflation, given that it is noncombustible, relatively inexpensive and highly soluble in blood, minimizing the risk of embolism<sup>2-3,6</sup>. However, PP increases intra-abdominal pressure, which has been shown to produce oliguria and renal dysfunction in both animal and clinical studies<sup>1-2,4-12</sup>. In healthy young patients, these changes tend to be mild and reversible due to the various physiologic mechanisms for CO<sub>2</sub> buffering and elimination<sup>2,12</sup>. Therefore, no major clinical consequences are observed. In patients with underlying renal impairment, however, these renal effects may be of clinical significance, thus increasing the morbidity of the procedure<sup>2-3,7,12</sup>. This situation is becoming common due to widespread use of laparoscopic techniques, which were formerly restricted to “optimal” candidates but are currently used in an increasing number of patients with comorbidities<sup>1-2,8-9</sup>. These adverse effects are also relevant in laparoscopic nephrectomies for live donor transplantation, due to concerns regarding possible PP-related graft damage<sup>1,4-5,13-14</sup>. Despite extensive research in the last two decades, the exact mechanisms responsible for the renal effects of PP have not been entirely elucidated<sup>5,12</sup>. Vascular and parenchymal compression certainly plays a role, though hormonal factors<sup>1-2,5-7,10-11</sup> and, more recently, oxidative stress<sup>4,9,13</sup> have been suggested as well. These last two factors could result at least partially from hypercarbia and acidosis, both caused by peritoneal absorption of CO<sub>2</sub><sup>2,4-6,8,10,14</sup>. McDougall *et al.*<sup>11</sup> demonstrated pressure-dependent CO<sub>2</sub> absorption through the peritoneal surface, which was not seen with argon insufflation. Other observations suggesting a pharmacological effect of CO<sub>2</sub>, inducing sympathetic and hormonal activation, have been reported. They include persistence of renal changes for some hours after desufflation<sup>1-2,5,8-11</sup>, increased renin activity in dogs following CO<sub>2</sub> (but not helium) insufflation<sup>10</sup> and higher vasopressin levels<sup>7,10</sup>, as well as complete oliguria, reversed with N-acetylcysteine<sup>9</sup> or a vasopressin receptor antagonist<sup>7</sup>. Histopathological changes have also been assessed, although they are reported only occasionally in the literature<sup>2,4,11,13-16</sup>.

The purpose of the present study is to evaluate the effects of pneumoperitoneum with carbon dioxide and helium on renal function and morphology in a rat model.

## Methods

All study procedures and protocols were reviewed and approved by the Animal Research Ethics Committee of the University of Brasilia, School of Medicine (CEUA, FM/UnB). Twenty-four male Wistar rats (Labocien, Centro Universitario de Brasilia, UniCEUB, Brasilia) weighing 275-370g and 90-120 days old were used in the study. Before the experiments, they were kept on a 12/12-h light/dark cycle and had access to water and chow *ad libitum*.

Anesthesia was induced and maintained with an IM injection of ketamine chloride and xylazine chloride at doses of 75 mg/kg and 10 mg/kg body weight respectively. A cystostomy was performed by percutaneous insertion of a 22-gauge vascular catheter 1 cm cephalad to the penis. The bladder was emptied and the urethra occluded at the distal penis to prevent urine leakage. The animals were randomized into three groups (n=8): gasless insufflation (‘open’, p=0 mmHg), carbon dioxide pneumoperitoneum at 12 mmHg, and helium pneumoperitoneum at 12 mmHg.

In all groups, a Veress needle was inserted percutaneously at the umbilicus (5 cm cephalad to the penis, approximately). In the CO<sub>2</sub> and helium groups, insufflation was performed with an automatic device (Surgiflator 16 L/min, World of Medicine, Germany) at a low flow rate (0.1 L/min). The gases were at room temperature. In the open group, no gas was injected. The selected intervention for each group was maintained for 90 minutes.

At the end of 90 minutes, the urine produced was collected, blood samples obtained through intracardiac puncture, and the left kidney of each animal removed for histopathological analysis. Finally, the rats were killed with an overdose of thiopental.

Blood samples were centrifuged. Both the serum obtained and the urine collected were frozen at -20°C and later tested in an automatic analyzer (ARCHITECT ci8200, Abbott Laboratories, United States). The following measurements were obtained: serum creatinine, urea, sodium, and potassium, and urinary volume, urea, and creatinine. Furthermore, creatinine clearance was estimated for the period and corrected for the weight of each animal.

The kidneys were immediately fixed in 10% buffered formalin and stained with hematoxylin and eosin. A pathologist blinded to group allocation evaluated all specimens under light microscopy. The following parameters were evaluated: hydropic degeneration, congestion, cytoplasmic vacuoles, membrane rupture and necrosis.

Data were expressed as means and standard deviations. Statistical analysis was performed using SPSS version 20.0. One-

way analysis of variance (ANOVA) was employed for among-group comparison of each variable. Tukey's post-hoc test was used as appropriate for comparison of pairs of groups (CO<sub>2</sub> vs. helium and CO<sub>2</sub> vs. open). p values ≤ 0.05 were considered significant.

**Results**

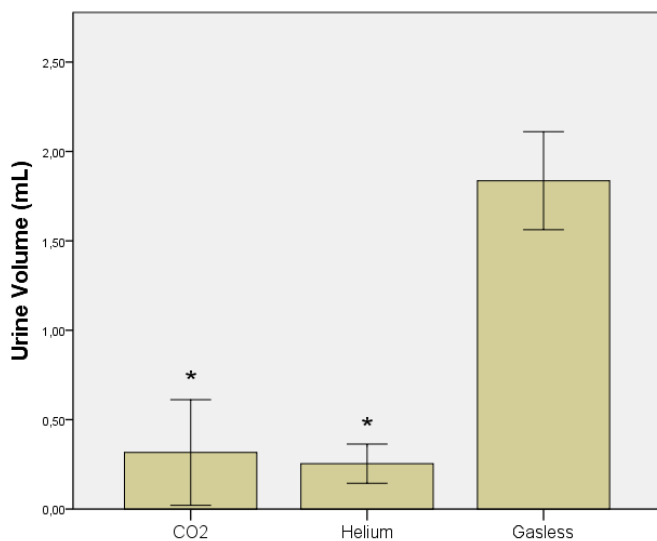
No animal died during the 90 minutes of the experiment. There was no difference in body weight or serum sodium, urea and creatinine among groups (Table 1).

**TABLE 1** – Serum creatinine, urea, sodium and body weight.

	CO <sub>2</sub>	Helium	Gasless	p*
<b>Weight (g)</b>	313 ± 27	309 ± 32	309 ± 28	0.95
<b>Creatinine (mg/dL)</b>	0.51 ± 0.06	0.54 ± 0.07	0.51 ± 0.06	0.70
<b>Urea (mg/dL)</b>	61 ± 7	60 ± 3	55 ± 9	0.88
<b>Na (mmol/L)</b>	132 ± 3	132 ± 3	131 ± 3	0.75

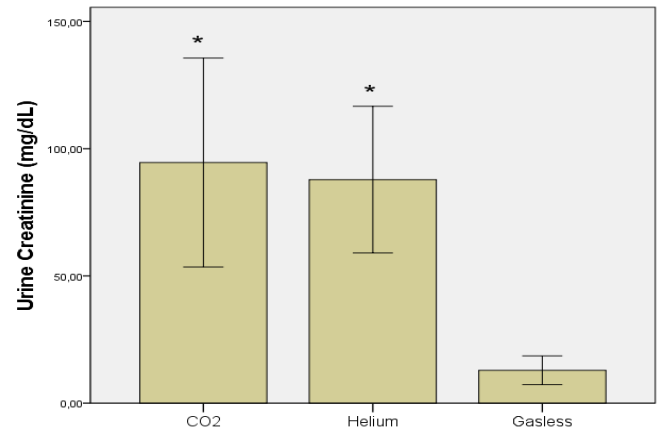
\*One-way analysis of variance (ANOVA)

Urinary output did not differ between the CO<sub>2</sub> and helium groups. In both, it was significantly lower than in the gasless insufflation group (Figure 1).



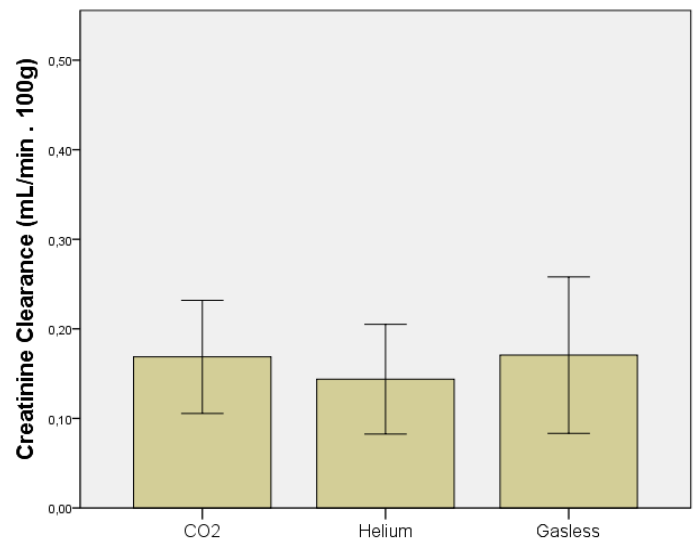
**FIGURE 1** – Urinary output after 90 minutes. \*p≤0.05 vs gasless.

Similarly, no difference was observed between the CO<sub>2</sub> and helium groups with respect to urine creatinine concentration, whereas in both, it was significantly higher than in the gasless group (Figure 2).



**FIGURE 2** – Urinary creatinine level. \*p≤0.05 vs gasless.

When creatinine clearance was estimated and corrected for the weight of each animal, no significant differences were found among the three groups (Figure 3).



**FIGURE 3** – Creatinine clearance per 100g body weight. \*p≤0.05 vs gasless.

Serum potassium was slightly increased in the helium group compared to the gasless insufflation group, though the difference was only significant in the CO<sub>2</sub> group (Figure 4).

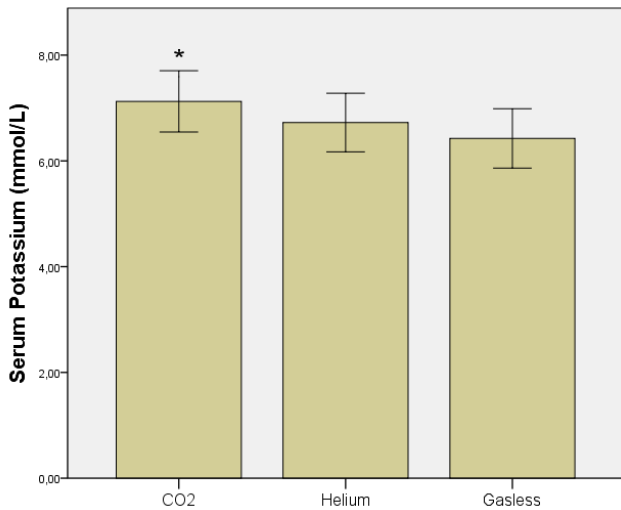


FIGURE 4 – Serum potassium concentration. \*p<0.05 vs gasless.

Finally, histopathological analysis revealed mild hydropic degeneration and vascular congestion in all groups, with no significant difference among them. No necrosis was observed (Table 2).

TABLE 2 – Histopathological analysis. The amount of each finding was quantified from 0 to 3. 0= absence, 1=mild, 2=moderate and three large amount.

	CO <sub>2</sub>	Helium	Gasless
Hydropic Degeneration	1	1	1
Congestion	1	1	1
Necrosis	0	0	0

### Discussion

Both groups subjected to PP exhibited oliguria, an effect repeatedly reported in previous studies<sup>4-11,16</sup>. No difference was observed regardless of whether CO<sub>2</sub> or helium was used for insufflation. Hence, at least under the conditions of this experiment, carbon dioxide did not have any additional oliguric effects as compared with an inert gas (helium). This finding is consistent with the few previous studies which employed gases other than CO<sub>2</sub> (argon, air, helium)<sup>5,10-11</sup>. Differences between the

gases were observed only after release of PP, when animals in the helium group were found to have significantly faster recovery of renal function than those assigned to the CO<sub>2</sub> group<sup>10</sup>. Not only did urinary output decrease, but urine also became more concentrated, as may be inferred from the rise in urine creatinine following PP. Once again, no difference was found between CO<sub>2</sub> and helium, indicating that both gases had similar effects on urine concentration. Similar levels of serum sodium, urea and creatinine between PP and control groups have also been reported elsewhere<sup>4,8,16</sup>. Serum potassium increased in the helium and CO<sub>2</sub> groups, although statistical significance was only reached in the latter. This might imply that hyperkalemia resulted from the combined effects of elevated intra-abdominal pressure and the metabolic effects of carbon dioxide.

A 12 mmHg pneumoperitoneum was chosen to warrant some degree of renal impairment, based on the experiments performed in rats by Kirsch *et al.*<sup>8</sup>. Thus any difference between CO<sub>2</sub> and Helium would become evident. Surprisingly, however, creatinine clearance did not differ among the three groups. This suggests that, in this experiment, oliguria following PP resulted from changes in overall water–electrolyte balance rather than from decreased renal function<sup>7</sup>. Whereas many studies report renal dysfunction<sup>7,1,9</sup>, it is certainly not a consensus finding in the literature, whereas oliguria is. Demyttenaere *et al.*<sup>12</sup> reviewed seven studies which used rodent models of PP, and in three, no change in renal function was found after PP. These inconsistencies are probably due to the difficulty of measuring renal function in the acute setting<sup>2,12</sup>, and this is also a limitation of the present study. Creatinine clearance is not as precise in the short term as it is chronically<sup>12</sup>, though it has been employed in some studies in this field<sup>10,11</sup>. Nevertheless, no ideal marker for acute renal function assessment is currently available, and the various methods that are available (creatinine and inulin clearance, radioisotopes, etc.) are mere approximations<sup>2,12</sup>. Another limitation of the experiment was the relatively short duration of PP (90 minutes). Some studies employed longer periods (as long as 24h<sup>16</sup>), and renal impairment increased proportionally. Therefore, a possible effect of CO<sub>2</sub> on renal function might need more time to become evident. The choice of a 90-minute PP period was based on the duration of most laparoscopic procedures.

Finally, observation of histopathological changes in kidney tissue after PP varies in the literature<sup>2</sup>. Many methods, such as H&E staining, von Kossa staining, apoptosis markers and immunohistochemistry have been used. The timing of kidney tissue examination also differs across different studies, ranging from immediately after PP<sup>13,16</sup> to some hours<sup>11</sup>, days<sup>15</sup> and even

a year after PP<sup>14</sup>. Only one study has reported transient changes directly related to the insufflation pressure applied<sup>16</sup>, whereas all other investigations have failed to observe any significant histopathological changes<sup>11,13-16</sup>.

### Conclusions

Under the conditions of this experiment, the type of gas used for induction of pneumoperitoneum resulted in no difference in the variables of renal function and morphology assessed. A combined effect of increased intra-abdominal pressure and metabolic effects of carbon dioxide is suggested by the serum potassium increase which was observed both in the CO<sub>2</sub> and in the helium groups, but only attained significance in the former compared with gasless insufflation. For the remaining variables, the effects of increased intra-abdominal pressure probably predominate over the metabolic effects of carbon dioxide.

### References

1. Cisek LJ, Gobet RM, Peters CA. Pneumoperitoneum produces reversible renal dysfunction in animals with normal and chronically reduced renal function. *J Endourol.* 1998;12(2):95-100.
2. Grabowsky JE, Talamini MA. Physiological effects of pneumoperitoneum. *J Gastrointest Surg.* 2009;13(5):1009-16.
3. Rademaker BMP, Bannenberf JJ, Kalkman CJ, Meyer DW. Effects of pneumoperitoneum with helium on hemodynamics and oxygen transport: a comparison with carbon dioxide. *J Laparoendosc Surg.* 1995;5(1):15-20.
4. Khoury W, Jakowlev K, Fein A, Orenstein H, Nakache R, Weinbroum AA. Renal apoptosis following carbon dioxide pneumoperitoneum in a rat model. *J Urol.* 2008;180:1554-8.
5. Wiesenthal JD, Fazio LM, Perks AE, Blew BDM, Mazer D, Hare G, Honey RJDA, Pace KT. Effect of pneumoperitoneum on renal tissue oxygenation and blood flow in a rat model. *Urology.* 2011;77(6):1508.e9-15.
6. Gutt CN, Oniu T, Mehrabi A, Schemmer P, Kashfi A, Kraus T, Büchler MW. Circulatory and respiratory complications of carbon dioxide insufflation. *Dig Surg.* 2004;21(2):95-105.
7. Dolgor B, Kitano S, Yoshida T, Bandoh T, Ninomiya K, Matsumoto T. Vasopressin antagonist improves renal function in a rat model of pneumoperitoneum. *J Surg Res.* 1998;79(2):109-14.
8. Kirsch AJ, Hensle TW, Chang DT, Kayton ML, Olsson CA, Sawczuk IS. Renal effects of CO<sub>2</sub> insufflation: oliguria and acute renal dysfunction in a rat pneumoperitoneum model. *Urology.* 1994;43(4):453-9.
9. Seguro AC, Poli de Figueiredo LF, Shimizu MH. N-acetylcysteine (NAC) protects against acute kidney injury (AKI) following prolonged pneumoperitoneum in the rat. *J Surg Res.* 2012;175(2):312-5.
10. Carmona M, Lopes RI, Borba M, Omokawa M, Naufal R, Miyaki K, Matsumura N, Vieira N, Pereira PRB. Comparison of the effects of carbon dioxide and helium pneumoperitoneum on renal function. *J Endourol.* 2008;22(5):1077-82.
11. McDougall EM, Monk TG, Wolf Jr JS, Hicks M, Clayman RV, Gardner S, Humphrey PA, Sharp T, Martin K. The effect of

- prolonged pneumoperitoneum on renal function in an animal model. *J Am Coll Surg.* 1996;182(4):317-28.
12. Demyttenaere S, Feldman LS, Fried GM. Effect of pneumoperitoneum on renal perfusion and function: a systematic review. *Surg Endosc.* 2007;21(2):152-60.
13. Akbulut G, Polat C, Aktepe F, Yilmaz S, Kahraman A, Serteser M, Gökçe C, Gökçe O. The oxidative effect of prolonged CO<sub>2</sub> Pneumoperitoneum on renal tissue of rats. *Surg Endosc.* 2004;18(9):1384-8.
14. Hazebroek EJ, de Bruin RWF, Bouvy ND, Marquet RL, Bonthuis F, Bajema IM, Hayes DP, Ijzermans JNM, Bonjer HJ. Long-term impact of pneumoperitoneum used for laparoscopic donor nephrectomy on renal function and histomorphology in donor and recipient rats. *Ann Surg.* 2003;237(3):351-7.
15. Farias IEC, Morais PHA, Durães LC, Carneiro FP, Oliveira, PG, Sousa JB. Effects of carbon dioxide pneumoperitoneum on hepatic and renal morphology of rats after segmental colectomy and colonic anastomosis. *Acta Cir Bras.* 2011;26(4):279-84.
16. Schachtrupp A, Toens Ch, Hoer J, Klosterhalfen B, Lawong AG, Schumpelick V. A 24-h pneumoperitoneum leads to multiple organ impairment in a porcine model. *J Surg Res.* 2002;106(1):37-45.

---

### Correspondence:

João Batista de Sousa  
Campus Universitário Darcy Ribeiro-UnB  
Faculdade de Medicina  
Laboratório de Cirurgia Experimental  
70910-900 Brasília – DF Brasil  
Tel.: (55 61)9984-2845  
sousajb@unb.br

Received: March 25, 2013

Review: May 27, 2013

Accepted: June 24, 2013

Conflict of interest: none

Financial source: National Council of Technological and Scientific Development (CNPq)

<sup>1</sup>Research performed at Experimental Surgery Laboratory, School of Medicine, University of Brasilia (UnB), Brazil.