



# Universidade de Brasília

## Repositório Institucional da Universidade de Brasília

*repositorio.unb.br*



**Este artigo** está licenciado sob uma licença Creative Commons Atribuição-NãoComercial 4.0 Internacional.

### **Você tem direito de:**

Compartilhar — copiar e redistribuir o material em qualquer suporte ou formato.

Adaptar — remixar, transformar, e criar a partir do material.

### **De acordo com os termos seguintes:**

Atribuição — Você deve dar o **crédito apropriado**, prover um link para a licença e **indicar se mudanças foram feitas**. Você deve fazê-lo em qualquer circunstância razoável, mas de maneira alguma que sugira ao licenciante a apoiar você ou o seu uso

Não Comercial — Você não pode usar o material para **fins comerciais**.

**Sem restrições adicionais** — Você não pode aplicar termos jurídicos ou **medidas de caráter tecnológico** que restrinjam legalmente outros de fazerem algo que a licença permita.



**This article** is licensed under a Creative Commons Attribution-NonCommercial 4.0 International License.

### **You are free to:**

Share — copy and redistribute the material in any medium or format.

Adapt — remix, transform, and build upon the material.

### **Under the following terms:**

Attribution — You must give **appropriate credit**, provide a link to the license, and **indicate if changes were made**. You may do so in any reasonable manner, but not in any way that suggests the licensor endorses you or your use.

NonCommercial — You may not use the material for **commercial purposes**.

**No additional restrictions** — You may not apply legal terms or technological measures that legally restrict others from doing anything the license permits.

Esta licença está disponível em: <https://creativecommons.org/licenses/by-nc/4.0/>

# Prospective study of Kawasaki disease complications: review of 115 cases

NATÁLIA RIBEIRO DE M. ALVES<sup>1</sup>, CRISTINA MEDEIROS R. DE MAGALHÃES<sup>2</sup>, ROSEANE DE FÁTIMA R. ALMEIDA<sup>3</sup>, REGINA CÂNDIDO R. DOS SANTOS<sup>4</sup>, LENORA GANDOLFI<sup>5</sup>, RICCARDO PRATESI<sup>6</sup>

<sup>1</sup>Medical Trainee, Pediatric Rheumatology Unit, Hospital de Base de Brasília, Brasília, DF, Brazil

<sup>2</sup>Ph.D. in Health Sciences; Attending Pediatric Rheumatologist Physician, Pediatric Rheumatology Unit, Hospital de Base de Brasília; Professor, Medical School, Escola Superior de Ciências da Saúde, Brasília, DF, Brazil

<sup>3</sup>M.D., Specialized in Echocardiography; Attending Cardiologist, Cardiology Service, Hospital de Base de Brasília, Brasília, DF, Brazil

<sup>4</sup>Ph.D. in Ophthalmology; Attending Ophthalmologist, Ophthalmology Service, Hospital de Base de Brasília; Professor, Medical School, Escola Superior de Ciências da Saúde, Brasília, DF, Brazil

<sup>5</sup>Ph.D. in Gastroenterology; Post-doctorate in Autoimmune Diseases; Attending Physician and Professor, Medical School, Post-Graduation Programs in Medical Sciences and Sciences of Health, Universidade de Brasília, Brasília, DF, Brazil

<sup>6</sup>Ph.D. in Immunology and Applied Genetics; Post-doctorate in Autoimmune Diseases; Professor Emeritus, Medical School, Universidade de Brasília, Brasília, DF, Brazil

## SUMMARY

**Objective:** To draw attention to complications that might arise in any Kawasaki disease (KD) stage, risk factors contributing to the onset of complications and possible transient or permanent disease sequelae. **Methods:** Prospective study (clinical cohort) conducted between April 2002 and April 2009 of 115 patients with KD admitted to the Pediatric Rheumatology Clinic of the General Hospital of the Federal District, Brazil. All patients were sequentially assessed with clinical and laboratory examinations, Doppler echocardiography, imitanciometry, auditory evoked potentials, psychological evaluation, ophthalmologic examination and, in one patient with chorea, cerebral magnetic resonance angiography. In all patients, a questionnaire assessing the possible presence of cognitive, emotional, behavioral and social disorders was applied. **Results:** Twenty-five patients (21.7%) had coronary aneurisms. Thirty-eight patients (33%) had a sensorineural auditory loss during the acute and subacute phases of the disease and 13 patients (11.3%) maintained the auditory loss six months after the first assessment. Other complications observed were as follows: facial palsy in one patient (0.9%), ataxia in acute and subacute phases in 11 (9.5%); 15 patients had ophthalmologic complications (13.2%), with uveitis in 13, papilledema in one patient, and conjunctival hemorrhage in another patient. One patient experienced chorea (0.9%), with a magnetic resonance angiography showing changes consistent with cerebral ischemia. In one patient, a thoracic aorta aneurism was found (0.9%) and another patient had a necrotizing vasculitis progressing to peripheral gangrene and tongue tip loss (0.9%). Behavioral changes over convalescence were observed in 23 children. **Conclusion:** KD may progress with several complications even within months of the disease acute phase, eventually resulting in permanent sequelae. The earlier the diagnosis and therapeutic intervention with IV IgG administration are, the lower will be the occurrence of complications; the presence of thrombocytosis, anemia and elevated and extended inflammatory activity are risk factors for complication arising.

**Keywords:** Mucocutaneous lymph node syndrome; coronary aneurism; aortic aneurism; sensorineural auditory loss; clinical course.

Study conducted at Pediatrics Service, Pediatric Rheumatology Unit, Hospital de Base de Brasília, Secretary of Health of the Federal District, Brasília, DF, Brazil

Submitted on: 08/30/2010

Approved on: 03/09/2011

### Correspondence to:

Riccardo Pratesi  
SQN 212 – Bloco F – Apto. 605  
Asa Norte  
CEP: 70864-060  
Brasília – DF  
Phone: +55 61 3307-2134 (UnB);  
+55 61 3340-9192 (home);  
+55 61 9298-6028  
pratesir@unb.br  
or pratesir@gmail.com

Conflict of interest: None.

## INTRODUCTION

Kawasaki disease (KD), also known as mucocutaneous lymph node syndrome, is a primary vasculitis often seen in childhood, being mediated by IgA<sup>1</sup>, affecting more frequently small- and medium-size vessels and it can lead to a fibrinoid necrosis in vessel walls. The disease compromises vessels from the intima layer to the perivascular area, forming aneurisms in several different stages in a childhood polyarteritis. This is a systemic vasculitis, but preferentially found in coronary arteries<sup>2</sup>.

KD diagnosis is purely clinical, based on the presence of fever persisting for at least five days and further four out of five diagnostic criteria: limb changes, such as hand and/or foot erythema or swelling during the acute stage and fingertip scaling over convalescence; polymorphous exanthema; bilateral conjunctivitis with no purulent discharge, lip erythema and cracking, raspberry tongue, throat redness and anterior cervical adenopathy with a 1.5 cm or larger size. As there are no specific laboratory markers, a high level of suspicion is required, usually resulting in a rise in the number of cases diagnosed<sup>3</sup>.

The most severe complication of the disease is coronary vasculitis, leading to coronary artery changes and affecting 15%-20% of patients if left untreated<sup>4</sup>. These changes include aneurisms, coronary artery ectasias and stenoses, responsible for 2% of mortality. The intravenous immunoglobulin G (IVIG) administration over the 10 first days of the disease leads to a reduced coronary artery impairment of 3%-8% and mortality to 0.2%<sup>2,3</sup>.

Other KD complications have been described, such as aneurisms of other arteries: aortic aneurisms, with a higher number of reported cases involving the abdominal aorta<sup>5-7</sup>; axillary artery aneurism<sup>8</sup>; brachiocephalic artery aneurism<sup>9</sup>; aneurisms of iliac and femoral arteries, and renal artery aneurism<sup>10,11</sup>.

Gastrointestinal complications in KD are described in the literature as case reports similar to those observed in Henoch-Schönlein purpura, such as: intestinal obstruction<sup>12</sup>, colon swelling<sup>13</sup>, intestinal ischemia<sup>14</sup>, intestinal pseudo-obstruction<sup>15</sup> and acute abdomen<sup>16</sup>.

Ophthalmologic changes associated with KD have been described since the 1980's, being found as uveitis, iridocyclitis, conjunctival hemorrhage<sup>17-19</sup>, optic neuritis<sup>20</sup>, amaurosis and ocular artery obstruction<sup>21</sup>.

KD can also be found as necrotizing vasculitis, progressing into peripheral gangrene, according to a number of case reports<sup>22-24</sup> described in the literature.

The neurological complications per central nervous system (CNS) lesion are increasingly found in literature. The neurological complications found are meningoencephalitis<sup>25,26</sup>, subdural effusion<sup>27,28</sup>, cerebral hypoperfusion<sup>29</sup>, cerebral ischemia and infarct<sup>30</sup>, cerebellar infarction<sup>31</sup>, manifesting with seizures, chorea, hemiplegia, mental confusion, lethargy and coma<sup>8</sup> or even a cerebral infarction with no neurological manifestations<sup>30,31</sup>.

Other neurological complications from cranial nerve involvement are reported as ataxia<sup>3</sup>, facial palsy<sup>32-34</sup> and sensorineural auditory loss<sup>35-37</sup>.

The first description for hearing loss in KD was made by Suzuki *et al.*<sup>35</sup> in Japan in 1988. In 1992, Sundel *et al.*<sup>36</sup> assessed 40 patients by standard audiometry and BERA (Brainstem Evoked Response Audiometry) in patients who could not undergo an audiometry. Seven patients (17.5%) had a sensorineural auditory loss and 14 patients had an inconclusive result. In 2001, Knott *et al.*<sup>37</sup> reported another study where they performed an audiological assessment in 62 patients over the first thirty days of KD; from these, 13 had a sensorineural auditory loss and two patients kept the sensorineural auditory deficit in a second audiological assessment 10 days later.

Behavioral changes, such as attention deficits, learning deficits, emotional disorders (emotional lability, fear of night and night terrors) and internalization problems (anxious, depressive or aggressive behavior) have been described in studies in the literature<sup>38,39</sup> conducted on the basis of the questionnaires Child Behavior Check List (CBCL4-18/1991), Strengths and Difficulties Questionnaire (1997) and Parenting Stress Index (PSI/1983).

The purpose of the current study was to obtain data regarding KD complications and identify the incidence of these complications in a sample of 115 cases followed in a clinic specialized in pediatric rheumatology in Brasília, Brazil. The objective of the study was to draw attention to the diagnosis of KD complications that are likely to occur even after the acute and subacute stages of the disease, possible transient or permanent sequelae and risk factors for these complications.

## METHODS

A clinical cohort of patients with Kawasaki disease was used and followed in the Pediatric Rheumatology Clinic of Hospital de Base do Distrito Federal (HBDF). The study evaluated 115 patients having KD diagnosed in accordance with the American Heart Association (AHA)<sup>3</sup> criteria. The patients were seen at the Pediatric Rheumatology Clinic of the HBDF from April 2002 to April 2009 (inclusion criteria). The incomplete KD forms and the patients having conditions that could lead to the same complications assessed were excluded. All patients provided an informed consent to participate in the study, which was approved by the Research Ethics Committee of Brasilia Health Secretary.

All of the 115 patients were followed with sequential clinical and laboratory examinations, echocardiography, brainstem auditory evoked potential (BERA) study and imitancimetry, ophthalmologic assessment with biomicroscopy and fundus examination, and psychological evaluation over the follow-up. Only one patient having chorea underwent a magnetic resonance angiography. All patients were treated with intravenous immunoglobulin at the diagnosis.

Clinical and laboratory examinations, as well as the echocardiograms, were performed at the admission, one month later and thereafter three-month apart in the first year after the DK onset and six-month apart later, being performed by the same cardiologist and using the same echo-Doppler apparatus (ALOKA SSD 2200, with 2.5 and 5.0 MHz transducer made in Japan).

The ophthalmologic examination was performed during KD acute and subacute stages after the first examination in all patients.

A questionnaire based on questionnaires Child Behavior Check List (CBCL4-18/1991); Strengths and Difficulties Questionnaire (1997); Parenting Stress Index (PSI/1983), assessing cognitive, emotional, behavioral or social difficulties was applied to all patients 30 days after the acute phase. The patients having behavioral, emotional or cognitive disorders were given periodical psychological follow-up.

The imitanciometry was initially performed in all patients to exclude those with an hearing loss from conductive changes. The AZ7 INTERACOUSTICS (Denmark, 2000) imitanciometer was used in auditory assessment. The auditory assessment was made through Brainstem Evoked Potentials (BERA) in all patients over the first 30 days of disease and six months later in patients having a hearing loss initially. The equipment used for BERA was MEDELEC SAPHIRE IV PREMIERE PLUS (England, 1996) with silver surface electrodes in positions based on the international system 10-20-Fz, A1, A2.

### STATISTICAL ANALYSIS

The Pearson's chi-squared test was used to find the association between KD complication occurrence and the following variables: thrombocytosis (platelet level over 500,000); anemia with hemoglobin under 10 g/dL; ESR over 50 mm for more than 30 days and IVIG treatment in the acute phase and after the acute phase. Differences with a  $p < 0.05$  were considered statistically significant. The software SAS 9.2 for Windows was employed for data analysis.

### RESULTS

Out of 115 patients, 77 (67%) were males, and the patients' ages ranged from two months to 11 years, with a mean of 3.2 years. Eighty-five were Caucasian, 24 had a dark complexion, 1 was Afrodescendant and 5 were Japanese descendants. Seventy-four per cent of patients were younger than five years old.

All patients received intravenous immunoglobulin (IVIG) 2 g/kg/dose although only 58 (%) were given IVIG within the first 10 days of disease.

Twenty-five patients (21.7%) had coronary aneurisms, with four patients having aneurisms in both coronary arteries, one only on the right artery and 20 only on the left; two of them were middle-sized and the others were small. Out of the 25 patients having a coronary aneurism, four

patients were under six months old, and two were older than 5 years; 10 patients used gamma globulin in acute phase and 15 patients in the subacute phase.

One patient (0.9%) had a thoracic aorta aneurism diagnosed in the subacute phase through the histopathological study of the aneurism and the clinical history data.

Thirty-eight patients (33%) had a sensorineural auditory loss during the acute and subacute phases of the disease and 13 (11.3%) were keeping the hearing loss six months after the first assessment. Out of these 38 patients, 20 used gamma globulin in the subacute phase.

One patient had a facial palsy in the subacute phase and 11 patients (9.5%) had ataxia, with 30% in the acute phase and the others in the subacute phase. The presence of ataxia was observed in patients with high and extended inflammatory activity.

Fifteen patients (13.2%) had ophthalmologic complications: 13 had an anterior uveitis, one had a papilledema and another patient had a conjunctival hemorrhage, 40% in the acute phase, the others in the subacute phase, and these complications were not maintained in the second ophthalmologic assessment 30 days later.

A patient had a course with chorea six months after the acute phase and it was controlled by using valproate; the brain magnetic resonance angiography showed lesions consistent with brain ischemia near the caudate nucleus. The changes were still present in a magnetic resonance angiography performed one year after the first study.

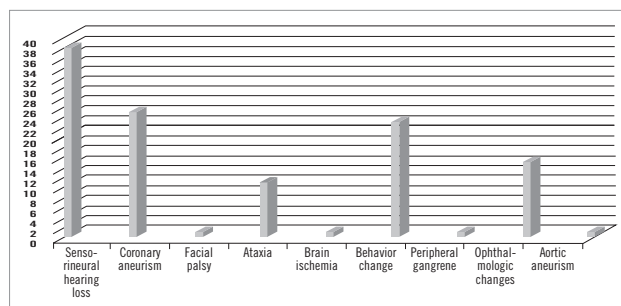
One patient with a high and extended inflammatory activity associated with anemia and thrombocytosis had a necrotizing vasculitis with peripheral gangrene and consequent tongue tip loss.

Twenty-three (20%) patients had behavioral changes over the convalescence: all of them had irritability, 13 had a course with aggressiveness, nine with an attention deficit, seven with a learning deficit and two with an antisocial behavior. Six patients remained with an aggressive behavior, three with a learning deficit and five with an attention deficit six months after the acute phase.

Among the patients with a coronary aneurism, 4 kept the small left coronary artery aneurism for 9 months, two years, two and a half years and one patient has been keeping a medium right coronary artery aneurism six years after the KD acute phase.

Five patients (4.3%) had an acute phase recurrence. Three of them used IVIG and two of them had a coronary aneurism. The other two used gamma globulin in the subacute phase and one of them had a course with a coronary aneurism.

The most prevalent complications were: sensorineural auditory loss (33%), coronary artery aneurisms (21.7%), behavior and cognitive disorders (20%), ocular changes (13.2%), ataxia (9.5%), facial palsy (0.9%), peripheral gangrene (0.9%), aortic aneurism (0.9%), cerebral ischemia (0.9%) (Figure 1).



**Figure 1** – Incidence of KD complications in a sample of 115 patients referred to the Pediatric Rheumatology Clinic of HBDF from January 2002 to January 2011.

The persistent complications were: coronary aneurism in four patients, sensorineural hearing loss in 13, behavioral changes in six patients.

The complications were more frequent in patients having more anemia, more thrombocytosis and higher and longer inflammatory activity (Table 1). The incidence of complications in KD was higher in patients using IVIG after the ten days of disease progress (Table 2). By statistical analysis, a significant association between frequency of complications and the following variables could be detected: anemia with Hb < 10 g/dL (p = 0.0001); thrombocytosis (p = 0.0015); ESR > 50 mm/h for longer than 30 days (p = 0.0001); and IVIG treatment after the acute phase (10 first days of disease) (p = 0.0111).

**DISCUSSION**

Takahashi *et al.*<sup>40</sup> observed in post-mortem studies of children having KD with no echocardiography abnormalities and dying years later from other causes that coronary arteries were markedly abnormal, with impressive proatherosclerotic changes persisting even in the absence of acute lesions in this artery. This cardiovascular damage unrecognized or unidentified in the acute phase will manifest later as a cardiovascular disease in the adult, explaining many myocardial infarction in adolescents and young adults with no apparent cause<sup>41</sup>.

Coronary aneurisms were classified by a new guideline by AHA<sup>3</sup> as small aneurisms (inner diameter from 3 to 5 mm), medium aneurisms (5 to 8 mm) and giant (> 8 mm). Other changes that can be found in KD even in the absence of aneurisms are vessel ectasias or stenoses. Giant coronary aneurisms have a higher risk for thrombosis, calcification and/or stenosis and consequently myocardial infarction. Small- and medium-size aneurisms usually regress spontaneously and rarely generate other complications<sup>3</sup>.

Aortic aneurisms should also be assessed for and the aortic diameter should be measured with imaging studies because there are evidence the aorta dilation is common in patients with KD and these dilations do not regress over the first year of the disease<sup>5</sup>.

The incidence of CNS involvement in KD ranges from 1.1% to 3.7%<sup>25,41</sup>, being found as seizures, ataxia, coma, lethargy, subdural effusion, hemiplegia, facial palsy and sensorineural hearing loss.

The facial palsy is often unilateral and more frequent on the left, being transient and seemingly associated with coronary impairment. It resolves spontaneously and completely, leaving no sequelae. Poon *et al.*<sup>32</sup> published a study in 2000 of 28 patients with facial palsy as a KD complication in patients with 3 to 25 months of age, preferentially in females with a 1.4:1 ratio, being transient over a range from two days to three months, more frequent on the left; 54% of the patients also had a coronary aneurism, but only one patient had used IV gamma globulin. In the current study, the only patient showing a facial palsy was diagnosed on the 26<sup>th</sup> day of disease, experiencing extended fever, high and long-lasting inflammatory activity. The facial palsy had an onset in the subacute phase on the left and improved within 30 days with physical therapy and the patient also had ataxia, hearing loss and a small left coronary aneurism. It is important to have a raised suspicion level for KD in children with extended fever and facial palsy.

Sensorineural hearing loss, seldom mentioned in literature, is another serious complication, possibly irreversible<sup>37,42</sup>. Sensorineural hearing loss in KD might reflect

**Table 1** – Relationship between KD complications and the presence of thrombocytosis (platelet count > 500,000), anemia with hemoglobin (Hb) < 10 mg/dL and ESR > 50 mm/h for over 30 days

	Patients [n]	Platelets [> 500,000] n (%)	Anemia [Hb <10 mg/dL] n (%)	ESR (> 50 mm/h) over 30 days n (%)
With KD complications	63	44 (70)	38 (62)	55 (87)
Without KD complications	52	21 (40)	13 (25)	23 (44.2)

**Table 2** – Relationship between KD complications and IV immunoglobulin use over the acute phase and after the acute phase

	Patients (n)	IVIG over the acute phase, n (%)	IVIG after the acute phase, n (%)
With KD complications	63	25 (40)	38 (60)
Without KD complications	52	33 (63.4)	19 (36.6)



inner ear abnormalities because of an intense cochlea or wall vessel (*vasa nervorum* and perineural vessels) inflammation, leading to a vasculitis neuropathy<sup>43,44</sup>.

The number of cases published on sensorineural hearing deficit in KD seems underestimated. Reduced hearing acuity may be slight and transient, as the condition is seen in small children and it could not be perceived by parents. The hearing loss is often detected only by audiometry or, in small children in whom tone audiometry is difficult to be performed, by brainstem auditory evoked potential assessment (BERA)<sup>42</sup>. Unlike studies previously conducted, our study found a high percentage of patients with sensorineural auditory loss both in the first 30 days of disease (33%) and in an assessment six months later (11.3%). This difference was likely to occur because prior studies did not have BERA performed in all patients and when this occurred, the second assessment was done within a variable length of time<sup>36,37</sup>.

We agree with Knott *et al.*<sup>37</sup> that sensorineural hearing loss is a frequent complication in KD, but we disagree with these authors that persistent sensorineural hearing loss is rare, since we found 11.3% of our patients sustaining a hearing loss in an assessment six months later. Similarly, we agree with the study by Sundel *et al.*<sup>36</sup> that a high and extended inflammatory activity is a risk factor for hearing loss in KD, but we observed anemia and thrombocytosis are also predisposing factors to a hearing loss in KD<sup>42</sup>.

Ataxia occurs in the acute and subacute phases and is usually transient<sup>3</sup>. In our study, 30% of patients had ataxia in the acute phase and the others, in the subacute phase, with its disappearing over convalescence.

CNS lesions may occur and despite their severity, as shown in a number of case reports in literature<sup>29</sup>, they are mostly self-limited findings, whose clearing could take months, but could also leave sequelae, such as brain atrophy, ischemic lesions<sup>30</sup>, including cognitive and behavioral conditions<sup>39</sup>. Meningoencephalitis, subdural effusions, hypoperfused brain, ischemia, cerebral and cerebellar infarction are CNS changes also being frequently detected from the better KD recognition and from a more extended follow-up in these patients<sup>26-31</sup>. CNS lesions should always be considered in KD, mainly in severe cases with high and extended inflammatory activity and the presence of a coronary impairment with or without neurological manifestations<sup>31</sup>.

Post-mortem histopathological studies in cases of KD are scarce. Amano *et al.*<sup>43</sup> found ganglionitis and cranial and peripheral nerve neuritis, endoarteritis, periarteritis, choriomeningitis and leptomeningitis, in addition to atrophy, degenerative changes with neuron loss, marginal and subependymal gliosis and glial nodes around degenerated neurons in post-mortem study of 30 children affected by KD.

Ophthalmologic complications, according to case reports found in literature, occur in the acute and subacute

phases, are usually transient and clear within months of the acute phase<sup>18</sup>. Burns *et al.*<sup>45</sup> assessed 41 patients in KD acute phase and observed 27 patients with anterior uveitis (25 bilaterally), 5 patients with punctate keratitis and 3 with keratitis and uveitis. In the current study, 15 patients had ophthalmologic complications, such as anterior uveitis, papilledema and conjunctival hemorrhage, showing transiently in the acute and subacute phases.

Histologically, KD can be a vasculitis in the polyarteritis group with a whole-vessel wall involvement and as it progresses with vessel fibrinoid necrosis, because of the high inflammatory involvement of the vessel, it can reach the point of a necrotizing vasculitis up to a peripheral gangrene, as seen in case reports in literature<sup>22-24</sup>. The patient having necrotizing vasculitis progressed to peripheral gangrene with a tongue tip loss. This patient was diagnosed at the subacute phase as KD and showed high and extended inflammatory activity associated with a major thrombocytosis.

KD is associated with significant behavioral sequelae, such as concentration difficulty, emotional lability, hyperactivity, aggressiveness, difficulty in social relationship and others. These complications should be considered during the follow-up of KD patients and they should be referred to psychological evaluation. Studies based on Child Behavior Check List (CBCL4-18/1991), Strengths and Difficulties Questionnaire (1997), Parenting Stress Index (PSI/1983), such as the study by Conway *et al.*<sup>38</sup> in 2005, where anxiety, depression, conditions associated with the conduct (aggressiveness, hyperactivity, disobedience and argumentative behavior) were found in 40% of patients and few social interrelationship or school achievement changes were found. King *et al.*<sup>39</sup> 2000 study based on the same questionnaires, 34% of patients were found with a behavior change, such as attention deficit, learning deficit, emotional effects (fear of night and night terrors). Internalization problems predominated (anxious and depressive behavior). In the current study, 20% of patients had behavior changes predominating in agreement with Conway *et al.*'s<sup>38</sup> findings of conduct changes (aggressiveness, hyperactivity, argumentative behavior) and with King *et al.*<sup>39</sup> findings, with attention deficit, learning deficit and emotional effects (emotional lability) predominating for a period of six months after KD acute phase. The most frequent change, occurring usually in the acute phase, is irritability.

In the current study, the most prevalent KD complications were sensorineural hearing loss (33%), coronary aneurisms (21.7%) and behavior and cognitive disorders (20%). As a systemic vasculitis, KD can progress into several complications, some of them being transient and others possibly leading to permanent sequelae, such as coronary complications, which can lead to death. A number of complications can be persistent, as in the case of sequelae

caused by brain lesions, sensorineural hearing loss and behavior changes, possibly leading to residual disabilities with learning and interpersonal relationship damage.

From the data analysis, we can conclude the earlier the diagnosis and therapeutic intervention with IVIG are, the lower the occurrence of complications will be; the presence of thrombocytosis, anemia and high and extended inflammatory activity are risk factors for complications. In addition, maintaining an attentive and periodical patient follow-up is important, as many of these complications are late in onset and can become permanent.

## REFERENCES

- Rowley AH, Shulman ST, Spike BT, Mask CA, Baker SC. Oligoclonal IgA response in vascular wall in acute Kawasaki disease. *J Immunol.* 2001;166:1334-43.
- Burns JC, Glodé MP. Kawasaki disease syndrome. *Lancet* 2004;364:533-44.
- Newburger JW, Takahashi M, Gerber MA, Gewitz MH, Tani LY, Burns JC *et al.* Diagnosis, treatment, and long-term management of Kawasaki disease: a statement for health professionals from the Committee on Rheumatic Fever, Endocarditis, and Kawasaki Disease, Council on Cardiovascular Disease in the Young, American Heart Association. *Pediatrics* 2004;114:1708-33.
- Newburger JW, Takahashi M, Burns JC, Breiser AS, Chung KJ, Glode MP *et al.* The treatment of Kawasaki syndrome with intravenous gamma globulin. *N Engl J Med.* 1986;315:341-7.
- Ravekes WJ, Colan SD, Gauvreau K, Baker AL, Sundel RD, van der Veld ME. Aortic root dilation in Kawasaki disease. *Am J Cardiol.* 2001;87:919-22.
- Fuyama Y, Hamada R, Uehara R, Yano I, Fujiwara M, Matoba M *et al.* Long-term follow up of abdominal aortic aneurysm complicating Kawasaki disease: comparison of the effectiveness of different imaging methods. *Acta Paediatr Jpn.* 1996;38:252-5
- Miyake T, Yokoyama T, Shinohara T, Seto S, Oiki M. Transient dilatation of the abdominal aorta in infant with Kawasaki disease associated with thrombocytopenia. *Acta Paediatr Jpn.* 1995;37:521-5.
- Tizard EJ. Complications of Kawasaki disease. *Curr Paediatr.* 2005;15:62-8.
- Yang G, Thompson D, Warren A. Late-appearing brachiocephalic aneurysm: an atypical vascular sequella of Kawasaki disease. *Pediatr Cardiol.* 2009;30:197-9.
- Kim DS. Kawasaki disease. *Yonsei Med J.* 2006;47:759-72.
- Dhillon R, Clarkson P, Donald AE, Powe AJ, Nash M, Novelli FV *et al.* Endothelial dysfunction late after Kawasaki disease. *Circulation* 1996;94:2103-6.
- Yaniv L, Jaffe M, Shaoul R. The surgical manifestations of the intestinal tract in Kawasaki disease. *J Pediatr Surg.* 2005;40:1-4.
- Kim MY, Noh JH. A case Kawasaki disease with colonic edema. *J Korean Med Sci.* 2008;23:723-6.
- Beiler HA, Schmidt KG, Herbay A, Löffler W, Daum R. Ischemic small bowel strictures in a case of incomplete Kawasaki disease. *J Pediatr Surg.* 2001;36:648-50.
- Akikusa JD, Laxer RM, Friedman JN. Intestinal pseudo obstruction in Kawasaki disease. *Pediatrics* 2004;113:504-6.
- Zulian F, Falconi F, Zancan L, Martini G, Seccieri S, Luzzato C *et al.* Acute abdomen as presenting manifestation of Kawasaki disease. *J Pediatr.* 2003;142:731-5.
- Ohno S, Miyajima T, Higuchi M, Yoshida A, Matsuda H, Nagamatsu I *et al.* Ocular manifestations of Kawasaki disease (mucocutaneous lymph node syndrome). *Am J Ophthalmol* 1982;93:713-17.
- Burke MJ. Eye involvement in Kawasaki disease. *J Pediatr Ophthalmol. Strabismus* 1981;18:7-11.
- Anand S, Yang YC. Optic disc changes in Kawasaki disease. *J Pediatr Ophthalmol Strabismus* 2004;41:177-9.
- Yousef N, Alhmoed A, Mawri F, Kaddurah A, Diskin D, Abuhammour W. Bilateral optic neuritis in a patient with Kawasaki disease. *J Pediatr Infect Dis.* 2009;4:301-3.
- Farvardin M, Kashef S, Aleyasin S, Nabavizadeh SH, Sajjadi M, Safari M. Sudden Unilateral blindness in a girl with Kawasaki disease. *J Pediatr Ophthalmol Strabismus* 2007;44:303-4.
- Kim YN, Choi DY, Jung MJ, Jeon I. A case of refractory Kawasaki disease complicated by peripheral ischemia. *Pediatr Cardiol.* 2008;29:1110-4.
- Dogan OF, Kara A, Devrim I, Tezer H, Besbas N, Ozen S *et al.* Peripheral gangrene associated with Kawasaki disease and successful management using prostacycline analogue: a case report. *Heart Surg Forum* 2007;10:70-2.
- Bonté Y, Mahr A, Laroche L, Guillevin L, Robenau M. Peripheral gangrene in adult-onset Kawasaki disease. *Scand J Rheumatol.* 2005;34:71-3.
- Takagi K, Umezawa T, Saji T, Morooka K, Matsuo N. Meningoencephalitis in Kawasaki disease. No to Hattatsu. 1990;22:429-35.
- Tabarki B, Mahdhaoui A, Selmi H, Yacoub M, Essoussi AS. Kawasaki disease with predominant central nervous system involvement. *Pediatr Neurol.* 2001;25:239-41.
- Aoki N. Subdural effusion in the acute stage of Kawasaki disease (mucocutaneous lymph node syndrome). *Surg Neurol.* 1988; 29:216-7.
- Bailie NM, Hensey OJ, Ryan S, Allcut D, King MD. Bilateral subdural collections- an unusual feature of possible Kawasaki disease. *Eur Paediatr Neurol.* 2001;5:79-81.
- Ichiyama T, Nishikawa M, Hayashi T, Koga M, Tashiro N, Furukawa S. Cerebral hypoperfusion during acute Kawasaki disease. *Stroke* 1998; 29:1320-1.
- Fujiwara S, Yamano T, Hattori M, Fujiseki Y, Shimada M. Asymptomatic cerebral infarction in Kawasaki disease. *Paediatr Neurol.* 1992;8:235-6.
- Muneuchi J, Kusuhara K, Kanaya Y, Ohna T, Furuno K, Kira R *et al.* Magnetic resonance studies of brain lesions in patients with Kawasaki disease. *Brain Dev.* 2006;28:30-3.
- Poon LKH, Lun KS, Ng YM. Facial nerve palsy and Kawasaki disease. *HKMJ* 2000;6:224-7.
- Wright H, Waddington C, Geddes J, Newburger W, Burgner D. Facial nerve complications Kawasaki disease. *Pediatrics* 2008;122:783-5
- Li ST, Chiu NC, Chen MR. Facial palsy in Kawasaki disease: report two cases. *Acta Paediatr Taiwan* 2008;49:24-7.
- Suzuki H, Yanagawa T, Kihira S. Two cases of hearing loss associated with Kawasaki disease. *Clin Pediatr.* 1988;41:167-72.
- Sundel RP, Cleveland SS, Bener AS, Newburger JW, Mc Gill T, Baker AL *et al.* Audiologic profiles of children with Kawasaki disease. *Am J Otol.* 1992;13:512-5.
- Knott DP, Orloff LA, Harris JP, Novak RE, Burns JC. Sensorial hearing loss and Kawasaki disease: a prospective study. *Am J Otolaryngol.* 2001;22:343-8.
- Conway CD, Ahluwalia R, Henry L, Michie C, Wood L, Tulloh R. Behaviour sequelae following acute Kawasaki disease. *BMC Pediatrics* 2005;14:1471-8.
- King JW, Schlieper A, Birdi N, Cappelli M, Korneluk Y, Rowe PC. The effect of Kawasaki disease on cognition and behavior. *Arch Pediatr Adolesc Med.* 2000;154:463-8.
- Takahashi K, Oharaseki T, Nave S. Pathological study of post coronary arteritis in adolescents and young adults with reference to the relationship between sequelae of Kawasaki disease and atherosclerosis. *Pediatr Cardiol.* 2001;22:138-42.
- Terasawa K, Ichinose E, Matsuishi T, Kato H. Neurological complications in Kawasaki disease. *Brain Dev.* 1983;5:371-4.
- Magalhães CMR, Alves NRM, Oliveira KMA, Silva IMC, Gandolfi L, Pratesi R. Sensorial hearing loss: an underdiagnosed complication of Kawasaki disease. *J Clin Rheumatol.* 2010.
- Amano S, Hazam F. Neural involvement in Kawasaki disease. *Acta Pathol Jpn.* 1980;30:365-73.
- Pagnoux C, Guillevin L. Peripheral neuropathy in systemic vasculitides. *Curr Opin Rheumatol.* 2005;17:41-8.
- Burns JC, Joffe L, Sargent RA, Glode MP. Anterior uveitis associated with Kawasaki syndrome. *Pediatr Infect Dis.* 1985;4:258-61.