

Journal Pre-proof

Oral mucosal lesions in a COVID-19 patient: new signs or secondary manifestations?

Juliana Amorim dos Santos, Ana Gabriela Costa Normando, Rainier Luiz Carvalho da Silva, Renata Monteiro De Paula, Allan Christian Cembranel, Alan Roger Santos-Silva, Eliete Neves Silva Guerra



PII: S1201-9712(20)30447-1

DOI: <https://doi.org/10.1016/j.ijid.2020.06.012>

Reference: IJID 4317

To appear in: *International Journal of Infectious Diseases*

Received Date: 29 May 2020

Revised Date: 3 June 2020

Accepted Date: 4 June 2020

Please cite this article as: { doi: <https://doi.org/>

This is a PDF file of an article that has undergone enhancements after acceptance, such as the addition of a cover page and metadata, and formatting for readability, but it is not yet the definitive version of record. This version will undergo additional copyediting, typesetting and review before it is published in its final form, but we are providing this version to give early visibility of the article. Please note that, during the production process, errors may be discovered which could affect the content, and all legal disclaimers that apply to the journal pertain.

© 2020 Published by Elsevier.

Oral mucosal lesions in a COVID-19 patient: new signs or secondary manifestations?

Running title: Oral conditions in COVID-19 patient

CASE REPORT

Juliana Amorim dos Santos^a, Ana Gabriela Costa Normando^{a,b}, Rainier Luiz Carvalho da Silva^c,
Renata Monteiro De Paula^c, Allan Christian Cembranel^c, Alan Roger Santos-Silva^b, Eliete Neves
Silva Guerra^{a*}.

Affiliations

^a Laboratory of Oral Histopathology, Health Sciences Faculty, University of Brasilia (UnB),
Brasilia, Brazil.

^b Oral Diagnosis, Piracicaba Dental School, University of Campinas (UNICAMP), São Paulo,
Brazil.

^c Hospital Alvorada Brasília, Brasilia, Federal District, Brazil.

* Corresponding author:

Prof. Eliete Neves Silva Guerra; Health Sciences Faculty, University of Brasilia, Brasilia, Brazil.

Asa Norte, Brasília, DF, Brazil ZIP Code: 70910-900. E-mail: elieteneves.unb@gmail.com /

Phone number: + 55 61 996684988

ABSTRACT

Some oral manifestations have been observed in patients with coronavirus disease in 2019 (COVID-19). However, there is still a question about whether these lesions are due to coronavirus infection or secondary manifestations resulting from the patient's systemic condition. Thus, this article aims to report an additional case of the oral conditions in a patient diagnosed with COVID-19. Our patient, a sixty-seven-year-old Caucasian man, tested positive to coronavirus and presented oral manifestations such as recurrent herpes simplex, candidiasis, and geographic tongue. We support the argument that some oral conditions could be secondary to the deterioration of systemic health or due to treatments for COVID-19. The present case report highlights the importance of including dentists in the intensive care unit multi-professional team to improve oral health in critical patients not only COVID-19 patients. Also, to contribute to evidence-based and decision-making in managing infectious diseases.

Key Words: COVID-19; SARS-CoV-2; Oral conditions; Recurrent herpes simplex; Candidiasis; Geographic tongue; Case Report.

INTRODUCTION

The novel coronavirus disease 2019 (COVID-19) presents an important and urgent threat to global health. The novel coronavirus was initially named 2019-nCoV and officially as severe acute respiratory syndrome coronavirus 2 (SARS- CoV-2) (WHO, 2020). The lungs are the primary site of infection for COVID-19, with patients presenting symptoms ranging from mild flu-like symptoms to fulminant pneumonia and potentially lethal respiratory distress (Guan et al., 2020).

There have been some COVID-19 cases reporting oral manifestations (Chaux-Bodard et al., 2020; de Maria et al., 2020; Lechien et al., 2020; Martín Carreras-Presas et al., 2020; Putra et al., 2020). In this field, since oral health of COVID-19 patients can be affected by the infection, there is still doubt whether these manifestations could be a typical pattern resulting from the direct viral infection. Maybe, oral lesions can result from the systemic deterioration, considering the possibility of opportunistic infections and also adverse reactions of treatments. Therefore, the range of COVID-19 manifestations in the oral cavity has been considered of broad and current interest. The overall objective of this brief article was to report a relevant case of the oral manifestations in a COVID-19 patient.

CASE REPORT

On March 31st, 2020, a sixty-seven-year-old Caucasian man with a history of cruising the Brazilian coast in the past 30 days was admitted at Hospital Alvorada Brasília, Brasilia, Brazil. Ten days earlier, the patient developed respiratory symptoms and progressive dyspnea on exertion, in addition to fever and diarrhea. The patient was asked about symptoms of gustatory and olfactory disfunction, and he reported hypogeusia. In the medical history, the patient reported coronary

disease, already revascularized, systemic hypertension, autosomal dominant polycystic kidney disease, and kidney transplant, which led him to take immunosuppressants regularly and to use pharmacological prophylaxis for venous pulmonary thromboembolism with Enoxaparin sodium (Clexane® 20mg/day). A nasopharyngeal swab following reverse-transcription polymerase chain reaction (RT-PCR) for SARS-CoV-2 RNA amplification resulted in positive. Chest computed tomography evidenced bilateral diffuse hyperdense infiltrations in the so-called “ground glass” pattern affecting both lungs, leading to intensive care unit (ICU) admission for supplemental O₂. Thereafter, the patient underwent orotracheal intubation due to disease progression and respiratory failure, and the patient was treated with Hydroxychloroquine sulfate (Reuquinol®, 400mg/day), Ceftriaxone sodium (2g/day), and Azithromycin (Zitromax® 500mg/day) for seven days.

Due to clinical suspicion of pneumonia associated with mechanical ventilation, and worsening of the white blood cell count, a new antibiotic regimen was started with Meropeném (Meronem®, 1000mg, 8/8hs) and Sulfamethoxazole+Trimetropin (Bactrim®, 400mg +80mg, 1.5 ampule, 8/8hs) for 10 days. Then, the patient underwent a tracheostomy. Hemodialysis was performed with subsequent recovery of renal function. The mechanical ventilation was maintained with good recovery and the possibility of spontaneous breathing. Also, the patient returned to the use of immunosuppressants and pharmacological prophylaxis for venous and pulmonary thromboembolism with Enoxaparin sodium (Clexane® 60mg/day).

On the twenty-fourth day of hospitalization, the dentists (R.L.C.S. and R.M.P.) were called to assess a persistent white plaque on the tongue dorsum. This lesion was previously treated by the physicians with intravenous Fluconazole (Zoltec® 200mg/100mL, one bag a day for 10 days) and oral nystatin (100,000 IU/mL, 8/8h, for 30 days), but no regression was observed. In addition to the white plaque, the dentist also observed multiple pinpoint yellowish ulcers in the tongue dorsum

resembling the late stage of herpetic recurrent oral lesions (Fig. 1A). After a complete intraoral examination, no other lesions on the oral mucosa were observed, except for a nodule located in the lower lip, measuring approximately 1 cm in its largest diameter, suggestive of a reactive lesion (fibroma) that was confirmed by the patient's pre-existence. Tongue scrape culture was performed, which was compatible with *Saccharomyces cerevisiae*. Extremely viscous saliva was observed, and biopsies were not recommended due to the patient's systemic conditions. And, cutaneous lesions were not observed during the patient's physical examination. At this time, the patient kept the antifungals and was treated with chlorhexidine digluconate (0.12%) alcohol-free mouth rinses, in addition to daily applications of 1% hydrogen peroxide. The dentist also instructed the health team on the importance of maintaining oral hygiene care.

Two weeks after the first oral examination, the white lesions on the tongue dorsum showed almost complete resolution. In a new intraoral examination, it was observed that the patient presented an asymptomatic geographic tongue classified as severe, according to the severity index recently published (Picciani et al., 2019) (Fig. 1B), associated with fissured tongue.

The patient was discharged from the ICU and in the subsequent days, there was a prompt recovery. The patient had no fever and the physician had been able to gradually decrease oxygen flow, and antibiotic therapies were discontinued. At that moment, in a hospital apartment, he was conscious, oriented, and not dependent on oxygen therapy. Also, the patient had no complaints, preserved appetite, good water consumption, good urine volume, and afebrile.

On May 14th, the patient was discharged after forty-four days of hospitalization, also the dentist only prescribed oral health care. Ten days later, the patient sent us an intraoral image where it could be observed maintenance of geographic tongue but now classified as moderate, according to the severity index recently published (Picciani et al., 2019). In addition, a slightly erythematous

area could be seen in the right palatine tonsil region, however, the patient reported being asymptomatic (Fig. 1C).

DISCUSSION

Current research shows that coronavirus damage to respiratory and other organs could be related to the distribution of angiotensin-converting enzyme 2 (ACE2) receptors in the human system (Zou et al. 2020). Therefore, cells with ACE2 receptor distribution may become host cells for the virus and further cause inflammatory reactions in related organs and tissues, such as the tongue mucosa and salivary glands (Xu et al. 2020). Besides, available evidence has not established an efficient and safe pharmacological agent against COVID-19 yet, and the potential ones are related to several adverse reactions, including oral lesions (de Melo Filho et al. 2012; Godinho et al., 2020; Mehra et al., 2020; National Center for Biotechnology Information, 2020). In addition, COVID-19 acute infection, along with associated therapeutic measures, could potentially contribute to negative outcomes concerning oral health, likely leading to various opportunistic fungal infections, recurrent oral herpes simplex virus (HSV-1) infection, oral unspecific ulcerations, fixed drug eruptions, dysgeusia, xerostomia linked to decreased salivary flow, ulcerations and gingivitis as a result of the impaired immune system and/or susceptible oral mucosa (Dziedzic & Wojtyczka, 2020).

The oral conditions presented by our patient and other cases already reported (Martín Carreras-Presas et al., 2020; Putra et al., 2020) supports the hypothesis that they are highly suggestive of secondary lesions resulting from the deterioration of systemic health or due to treatments for COVID-19. Even considering our hypothesis of associated conditions, the relevance of the dentist as part of the multi-disciplinary team in supporting critical patients in ICU such as COVID-19 should be highlighted. Also, dental follow up after the patient is dismissed from the

hospital must be provided. In COVID-19 patients we should consider the occurrence of some oral signs and symptoms, including dysgeusia, petechiae, candidiasis, traumatic ulcers, HSV-1 infection, geographical tongue, thrush-like ulcers, among others. Thus, the importance of the clinical dental examination of patients with infectious diseases in the ICU should be emphasized, considering the need for support, pain control, and quality of life.

Ethical Approval and Informed Consent: The study has been conducted in full accordance with ethical principles (Declaration of Helsinki), and written informed consent was obtained from the patient.

Conflicts of Interest: None to declare.

Funding: Decanato de Pesquisa e Inovação, Universidade de Brasília, EDITAL DPI-UnB N° 04/2019 – (ENSG grant 33902001).

Author Contributions: ENSG, JAS and AGCN: Conceptualization, Study design, Literature research, Writing-original draft. RLCS, RMP and ACC: Clinical studies, Treat the patient, Data acquisition, Writing-review. ARSS: Validation, Writing-review.

REFERENCES

1. Chaux-Bodard A-G, Deneuve S, Desoutter A. Oral manifestation of Covid-19 as an inaugural symptom? *J Oral Med Oral Surg* 2020;26:18.
2. de Maria A, Varese P, Dentone C, Barisione E, Bassetti M. High prevalence of olfactory and taste disorder during SARS-CoV-2 infection in outpatients. *J Med Virol*. 2020 May 8. doi:

- 10.1002/jmv.25995.
3. de Melo Filho MR, da Silva CA, da Rocha Dourado M, de Oliveira Pires MB, Pêgo SP, de Freitas EM. Palate hyperpigmentation caused by prolonged use of the anti-malarial chloroquine. *Head Neck Pathol.* 2012;6(1):48- 50. doi:10.1007/s12105-011-0288-5.
 4. Dziejic A, Wojtyczka R. (2020), The impact of coronavirus infectious disease 19 (COVID- 19) on oral health. *Oral Dis.* Accepted Author Manuscript. doi:10.1111/odi.13359.
 5. Godinho GV, Paz ALLM., de Araújo Gomes EPA, Garcia CL, Volpato LER. Extensive hard palate hyperpigmentation associated with chloroquine use. *Br J Clin Pharmacol.* 2020 doi:10.1111/bcp.14313.
 6. Guan W, Ni Z, Hu Y, Liang W, et al. Clinical Characteristics of Coronavirus Disease 2019 in China. *N Engl J Med* 2020; 382:1708-1720. doi: 10.1056/NEJMoa2002032.
 7. Lechien JR, Chiesa-Estomba CM, De Siati DR, et al. Olfactory and gustatory dysfunctions as a clinical presentation of mild-to-moderate forms of the coronavirus disease (COVID-19): a multicenter European study. *Eur Arch Otorhinolaryngol.* 2020;1- 11. doi:10.1007/s00405-020-05965-1.
 8. Martín Carreras-Presas C, Amaro Sánchez J, López-Sánchez AF, Jané-Salas E, Somacarrera Pérez ML. Oral vesiculobullous lesions associated with SARS-CoV-2 infection. *Oral Dis.* 2020 May 5. doi: 10.1111/odi.13382.
 9. Mehra MR, Desai SS, Ruschitzka F, Patel AN. Hydroxychloroquine or chloroquine with or without a macrolide for treatment of COVID-19: a multinational registry analysis. *The Lancet*, 2020; 0(0). Published online May 22, 2020 [https://doi.org/10.1016/S0140-6736\(20\)31180-6](https://doi.org/10.1016/S0140-6736(20)31180-6).

10. National Center for Biotechnology Information. PubChem Database. Ritonavir, CID=392622, <https://pubchem.ncbi.nlm.nih.gov/compound/Ritonavir> (accessed on May 22, 2020).
11. Picciani BLS, Santos LR, Teixeira-Souza T, et al. Geographic tongue severity index: A new and clinical scoring system. *Oral Surg Oral Med Oral Pathol Oral Radiol.* 2020;129(4):330-338. doi:10.1016/j.oooo.2019.12.007.
12. Putra BE, Adiarto S, Dewayanti SR, Juzar DA. Viral Exanthem with "Pin and Needles Sensation" on Extremities of COVID-19 Patient. *Int J Infect Dis.* 2020 May 8. pii: S1201-9712(20)30327-1. doi: 10.1016/j.ijid.2020.05.020.
13. World Health Organization (2020), Novel Coronavirus(2019-nCoV) Situation Report – 22 - Data as reported by 11 February 2020* (https://www.who.int/docs/default-source/coronaviruse/situation-reports/20200211-sitrep-22-ncov.pdf?sfvrsn=fb6d49b1_2).
14. Xu, H., Zhong, L., Deng, J. et al. High expression of ACE2 receptor of 2019-nCoV on the epithelial cells of oral mucosa. *Int J Oral Sci* 2020; 12(8). doi: 10.1038/s41368-020-0074-x.
15. Zou X, Chen K, Zou J, Han P, Hao J, Han Z. Single-cell RNA-seq data analysis on the receptor ACE2 expression reveals the potential risk of different human organs vulnerable to 2019-nCoV infection. *Front Med.* 2020;14(2):185- 192. doi:10.1007/s11684-020-0754-0.

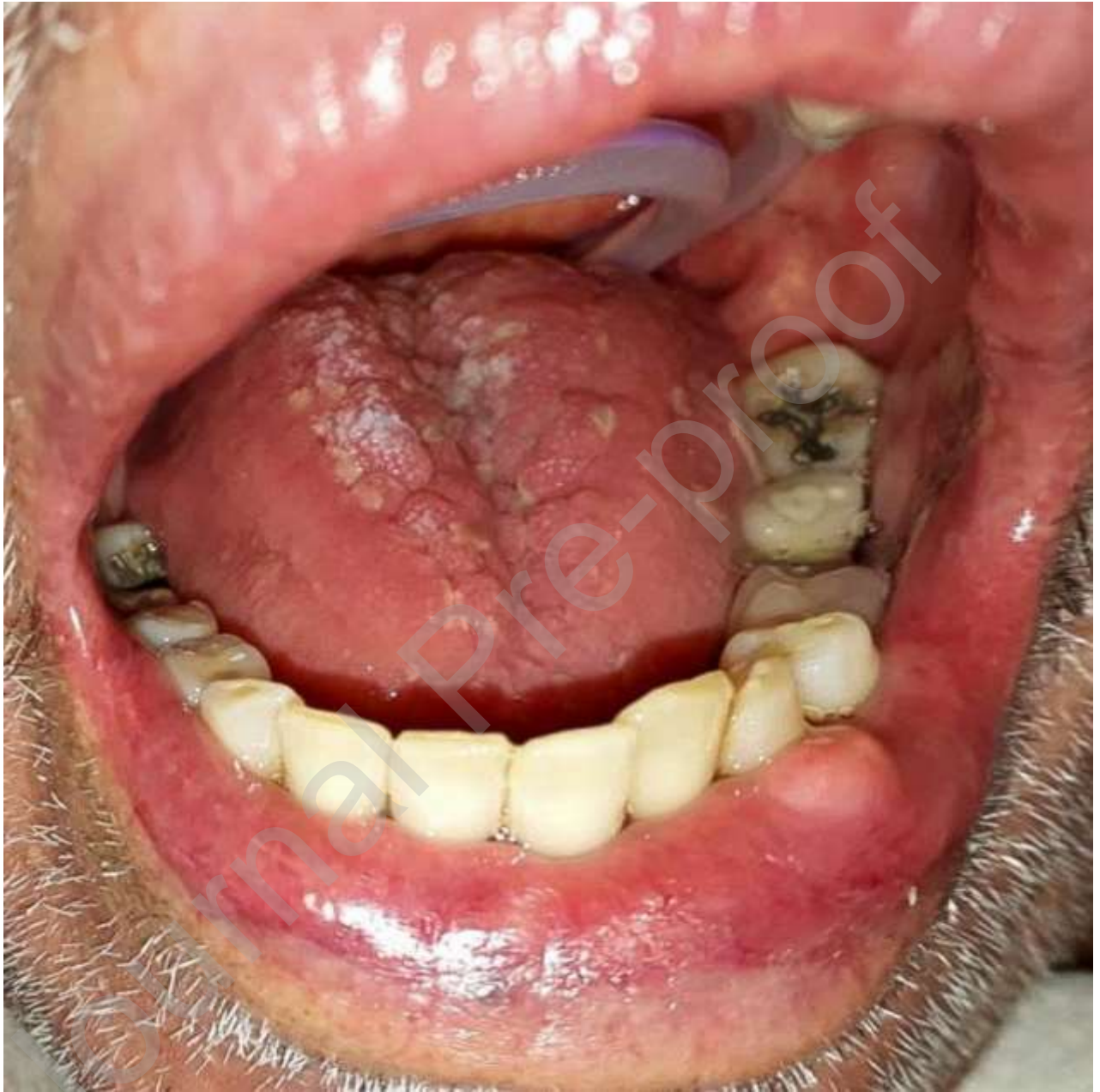FIGURE LEGENDS

Figure 1A – April 24th, 2020. COVID-19 patient presenting a white plaque on the tongue dorsum, centrally located, associated with several small, circle-shaped yellowish ulcers resembling the late stage of herpetic recurrent oral lesions associated with candidiasis. Also,

a nodule located in the lower lip, measuring approximately 1 cm in its largest diameter, suggestive of a reactive lesion (fibroma) that was observed.

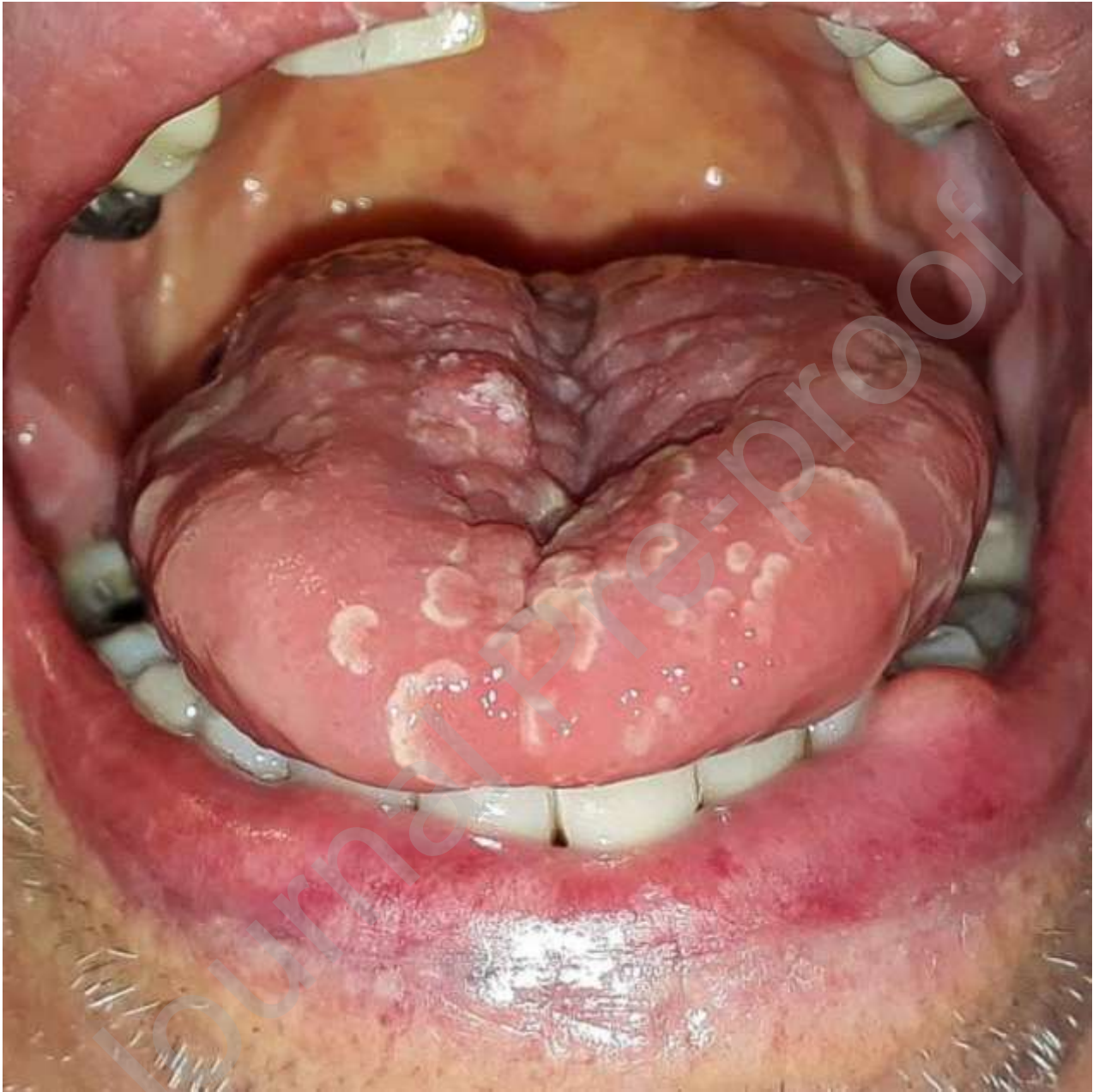


Figure 1B – May 7th, 2020. COVID-19 patient presenting atrophic areas surrounded by elevate yellow-white halo classified as severe geographic tongue according to the severity index scoring system (Picciani et al., 2019) associated with fissured tongue. Also, the tongue white lesions suggestive of candidiasis showed almost complete resolution.

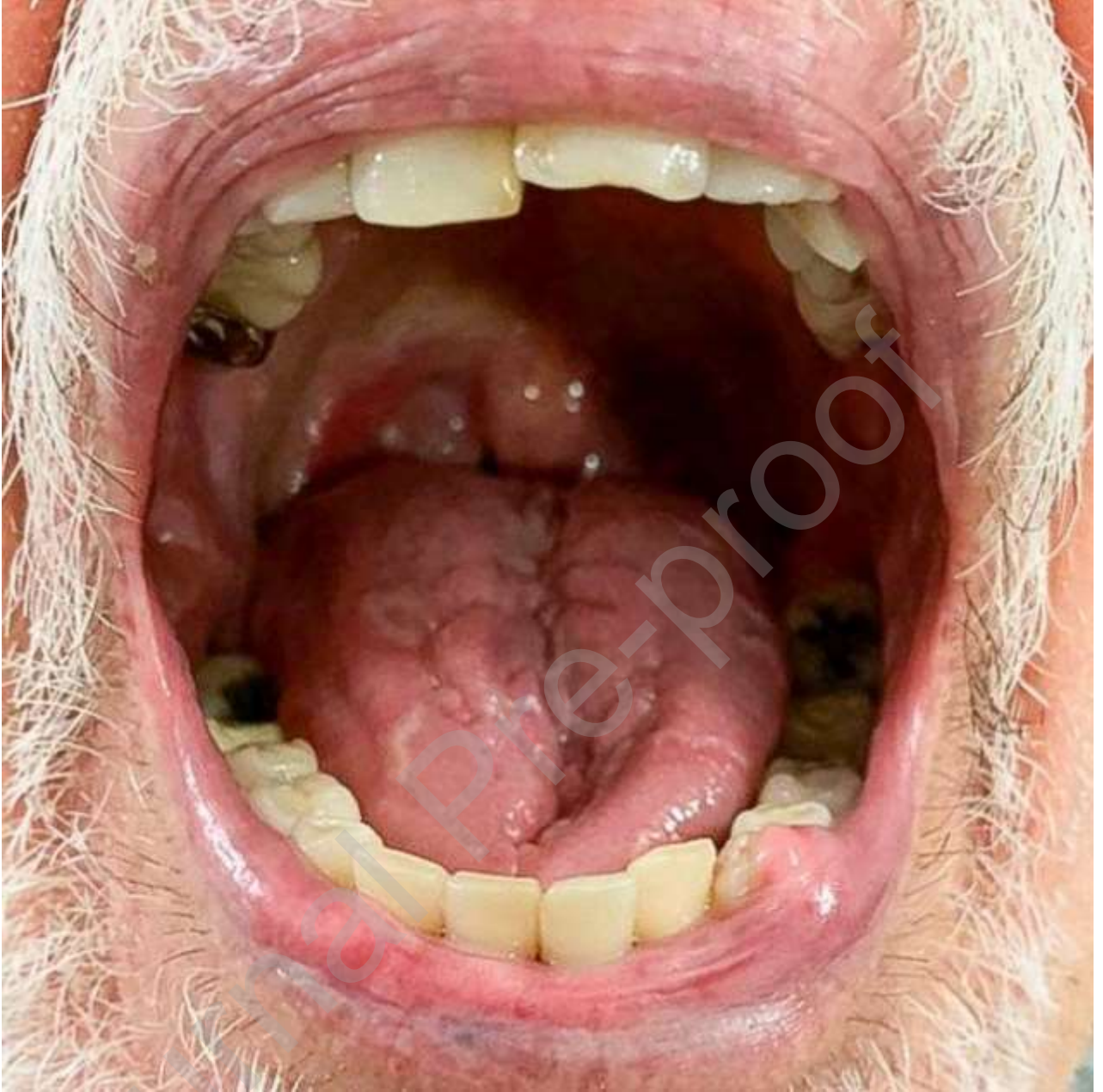

Figure 1C – May 25th, 2020. Patient recovered from COVID-19 showing atrophic areas surrounded by elevated yellow-white halo classified as moderate geographic tongue according to the severity index scoring system (Picciani et al., 2019). We also can observe a slightly erythematous area in the right palatine tonsil region, however, the patient reported being asymptomatic.