

This Accepted Author Manuscript is copyrighted and published by Elsevier. It is posted here by agreement between Elsevier and University of Brasilia. Changes resulting from the publishing process - such as editing, corrections, structural formatting, and other quality control mechanisms - may not be reflected in this version of the text. The definitive version of the text was subsequently published in [Animal Reproduction Science, Volume 91, Issues 3–4, February 2006, Pages 249–263, doi:10.1016/j.anireprosci.2005.04.013]. You may download, copy and otherwise use the AAM for non-commercial purposes provided that your license is limited by the following restrictions:

(1) You may use this AAM for non-commercial purposes only under the terms of the CC-BY-NC-ND license.

(2) The integrity of the work and identification of the author, copyright owner, and publisher must be preserved in any copy.

(3) You must attribute this AAM in the following format: [agreed attribution language, including link to CC BY-NC-ND license + Digital Object Identifier link to the published journal article on Elsevier's ScienceDirect® platform].

Este Manuscrito do Autor Aceito para Publicação (AAM) é protegido por direitos autorais e publicado pela Elsevier. Ele está disponível neste Repositório, por acordo entre a Elsevier e a Universidade de Brasília. As alterações decorrentes do processo de publicação - como a edição, correção, formatação estrutural, e outros mecanismos de controle de qualidade - não estão refletidas nesta versão do texto. A versão definitiva do texto foi posteriormente publicado em [Animal Reproduction Science, Volume 91, Número 3–4, Fevereiro 2006, Páginas 249–263 doi:10.1016/j.anireprosci.2005.04.013]. Você pode baixar, copiar e utilizar de outra forma o AAM para fins não comerciais, desde que sua licença seja limitada pelas seguintes restrições:

(1) Você pode usar este AAM para fins não comerciais apenas sob os termos da licença CC- BY-NC-ND.

(2) A integridade do trabalho e identificação do autor, detentor dos direitos autorais e editor deve ser preservado em qualquer cópia.

(3) Tem de atribuir este AAM no seguinte formato: [acordo na linguagem atribuída, incluindo o link para CC BY-NC-ND licença Digital + DOI do artigo publicado na revista Elsevier ScienceDirect® da plataforma].

Histological and ultrastructural analysis of cryopreserved sheep preantral follicles

Regiane R. Santos
Ana P.R. Rodrigues
Sonia H.F. Costa
José R.V. Silva
Maria H.T. Matosa
Carolina M. Lucci
Sonia N. Bão
Rob van den Hurk
José R. Figueiredo

Abstract

The aim of this study was to verify the histological and ultrastructural characteristics of sheep preantral follicles after exposure of ovarian tissue to cryopreservation in glycerol (GLY), ethylene glycol (EG), propanediol (PROH) or dimethyl sulfoxide (DMSO) in order to determine the optimum method to store sheep ovarian tissue for later experimental or clinical use. Each ovarian pair from five mixed-breed ewes was divided into 17 fragments. One (control) fragment was immediately fixed for routine histological and ultrastructural studies and the remaining (test) fragments were randomly distributed in cryotubes, equilibrated at 20 °C/20 min in 1.8 mL of minimal essential medium (MEM) containing 1.5 or 3 M GLY, EG, PROH or DMSO and then either fixed for morphological studies to determine their possible toxic effect or frozen/thawed and then fixed to test the effect of cryopreservation on preantral follicles. Histological analysis showed that, compared to control fragments, all cryoprotectants at both concentrations significantly reduced the percentage of normal preantral follicles in ovarian fragments prior to or after cryopreservation. PROH 3.0 M appeared to exert a more toxic effect ($P < 0.05$) than the other cryoprotectants in noncryopreserved tissues. After freezing/thawing, the highest ($P < 0.05$) percentages of lightmicroscopical normal preantral follicles were observed in ovarian fragments cryopreserved in EG (1.5 and 3 M) or DMSO (1.5 M). However, transmission electronic microscopical (TEM) examination showed that only the DMSO-cryopreserved preantral follicles had normal ultrastructure. The data suggest that sheep preantral follicles should be cryopreserved with 1.5 M DMSO for later clinical or experimental application.

Keywords: Preantral follicles; Ovine; Toxicity test; Cryopreservation

1. Introduction

Successful cryopreservation is a cellular dehydration process that prevents or reduces the damage caused by ice crystal formation (Shaw et al., 2000). To this end a cellular permeating cryoprotectant is used to protect the cells during their storage at low temperatures. Cryopreservation of embryos, ovarian tissue and gametes is a promising technique/approach to preserve the fertility of mammalian species, including endangered species and young cancer patients. It offers the advantage of storing large numbers of follicles

that could be subsequently transplanted or cultured in vitro to obtain mature oocytes. Recently, various scientists (Cox et al., 1996: mouse; Oktay et al., 1998: woman; Amorim et al., 2003a and Amorim et al., 2003b: sheep; Rodrigues et al., 2004a and Rodrigues et al., 2004b: goat; Lucci et al., 2004: cow) have shown that it is possible to cryopreserve immature oocytes enclosed in preantral follicles. After cryopreservation, isolated preantral follicles are capable to grow in vitro (Candy et al., 1995: mouse; Hovatta et al., 1996: human; Cecconi et al., 2004: sheep). Cryopreservation of ovarian tissue fragments have also led to the resumption of the reproductive cycle after transplantation (Harp et al., 1994: mouse; Candy et al., 1995: mouse; Baird et al., 1999 and Salle et al., 1999: sheep), while transplantation of mouse frozen/thawed ovarian tissue led to birth of viable animals (Carroll and Gosden, 1993, Gunasena et al., 1997a and Gunasena et al., 1997b). In domestic animals, follicular viability in frozen/thawed ovarian tissue can be estimated through histological (Amorim et al., 2003a and Amorim et al., 2003b: sheep) and ultrastructural (Rodrigues et al., 2004a and Rodrigues et al., 2004b: goat; Lucci et al., 2004: cow) analysis.

The main cryoprotectants that are used for embryos, oocytes and ovarian tissue are glycerol (GLY), dimethyl sulfoxide (DMSO), propanediol (PROH) and ethylene glycol (EG). In studies with sheep ovarian tissue, the effects of DMSO and EG have been studied (Amorim et al., 2003a and Amorim et al., 2003b; Cecconi et al., 2004). In Amorim's studies, routine histology and trypan blue test were used to evaluate the quality of isolated primordial follicles after freezing and thawing. Cecconi et al. studied in vitro growth of multilaminar (secondary) follicles, using both histological and biochemical parameters (oestradiol determination and intercellular metabolic cooperativity).

The aim of this histological and ultrastructural study was to compare the effects of four cryoprotectants (GLY, DMSO, PROH and EG) in two concentrations (1.5 and 3.0 M), in order to identify the best one(s) to preserve sheep preantral follicles.

2. Materials and methods

2.1. Source and preparation of ovarian tissue

Ovaries (n = 10) from adult mixed breed sheep (n = 5) were obtained at a local slaughterhouse. The ovaries were trimmed of adhering tissue, washed in 70% alcohol and then, twice in 0.9% saline solution. The ovaries were put into tubes containing 20 mL of 0.9% saline solution and transported to the laboratory within 1 h in a thermosflask filled with water

at 20 °C. From each ovarian pair, a (control) fragment was dissected. The larger part of this fragment was fixed in Carnoy's fluid for 12 h for routine histological studies. A smaller part of the control fragment was fixed in paraformaldehyde/glutaraldehyde solution (paraformaldehyde 2% and glutaraldehyde 2.5% in sodium cacodylate buffer 0.1 M, pH 7.2) for transmission electron microscopical (TEM) studies. Subsequently, each pair of ovaries was divided into 16 fragments of approximately 3 mm × 3 mm × 1 mm and subjected to a toxicity test (n = 8) or freezing/thawing (n = 8) as described below.

2.2. Toxicity test

Toxicity tests were performed to study the effects of DMSO, PROH, GLY or EG at two concentrations (1.5 and 3.0 M) on follicles in ovarian tissue fragments. To this end, ovarian fragments (n = 8) were exposed for 20 min at 20 °C (equilibration period) in cryotubes to 1.8 mL of minimum essential medium (MEM) containing DMSO, PROH, GLY or EG at 1.5 or 3 M. After the equilibration period, the cryoprotectants were immediately removed from the tissue according to the method described by Candy et al. (1997). Briefly, the fragments were rinsed three times for 5 min in MEM supplemented with 10% fetal bovine serum (MEM+) at room temperature. Finally, the ovarian fragments were fixed for histological and ultrastructural studies as described in the former paragraph. Each cryoprotectant and each concentration was tested on an ovarian fragment of five different animals.

2.3. Freezing and thawing procedures

For freezing, ovarian fragments (n = 8) were individually placed in 2.0 mL vials and equilibrated in 1.8 mL MEM+ with cryoprotectants (DMSO, PROH, GLY or EG) at the same concentrations and equilibration period as used in the toxicity test. After equilibration, the vials with the ovarian tissue were transferred to a computerized programmable freezer (Freeze Control, CryoLogic Pty Ltd., Waverley, Australia) at 20 °C. The vials were cooled at 2 °C/min to -7 °C and ice crystal formation (seeding) was induced manually by touching the vials with forceps pre-chilled in liquid nitrogen. The specimens were held at this temperature for 15 min, then cooled at 0.3 °C/min to -30 °C and thereafter at 0.15 °C/min to -33 °C. The vials were then plunged directly into liquid nitrogen (-196 °C) and stored for up to 5 days before thawing.

For thawing, the vials were taken from the liquid nitrogen, warmed at room temperature for approximately 1 min and immersed in a water bath at 37 °C until the ice melted. The cryoprotectant was then removed as described above for the toxicity test; thereafter, the ovarian fragments were fixed for histological and ultrastructural examination. Five replicates, each derived from a different animal, were used for each concentration of cryoprotectant tested.

2.3.1. Histological analysis

After fixation in Carnoy's fluid, ovarian fragments were dehydrated in ethanol, clarified with xylene and embedded in paraffin wax. Serial sections (7 µm) of ovarian tissue were cut and every fifth section was mounted on glass slides and stained with periodic acid Schiff (PAS)-hematoxylin. All sections were examined using a light microscope (Leica) at magnifications 20× and 40×. Preantral follicles were defined as follicles with an oocyte surrounded either by one flattened and/or cuboidal layer or several layers of only cuboidal granulosa cells. To avoid counting a follicle more than once, preantral follicles were counted only in the sections where their oocyte nucleus was observed. Follicular quality was evaluated based on the morphological integrity of the oocyte, the granulosa cells and the basement membrane. Preantral follicles were classified as (i) histologically/morphologically normal when they contain an intact oocyte and intact granulosa cells, (ii) degenerated grade 1 when their oocyte nucleus has become pycnotic, and (iii) degenerated grade 2 when the oocyte is shrunken and its nucleus pycnotic and, when possibly granulosa cells have detached from the basement membrane and have enlarged in volume.

2.4. Ultrastructural analysis

For better evaluation of the follicular morphology, ultrastructural studies were carried out on fragments of control ovaries and ovaries that were frozen/thawed in presence of DMSO or EG, the cryoprotectants which appeared the best in maintaining the histological image of follicles. For this, tissue fragments with a maximum dimension of 1 mm³ were fixed in 2% paraformaldehyde and 2.5% glutaraldehyde in 0.1 M sodium cacodylate buffer (pH 7.2) for 3 h. After fixation and five washes, specimens were post-fixed in 1% osmium tetroxide, 0.8% potassium ferricyanide and 5 mM calcium chloride in 0.1 M sodium cacodylate buffer for 1 h. Subsequently, the samples were dehydrated through a gradient of acetone solutions (31–

100%) and the tissues were embedded in Spurr. Semi-thin sections (3 μm) were stained with toluidine blue. The ultra-thin sections (60–70 nm) were contrasted with uranyl acetate and lead citrate, and examined under a Jeol JEM 100 C transmission electron microscope.

2.5. Statistical analysis

All treatment data from 2972 preantral follicles were analysed using a factorial design (cryoprotectant effects: GLY \times PROH \times DMSO \times EG, concentration: 1.5 \times 3 M, and test: toxicity \times cryopreservation) in an ANOVA test. The data were transformed in $(x + 1)^3$. The means were compared by the Tukey test. The comparison of the percentage of morphologically normal preantral follicles in treatments in relation to the control was analyzed by a Chi-square test. Values were considered statistically significant when $P < 0.05$.

3. Results

3.1. Percentage of normal preantral follicles after toxicity test and cryopreservation

A total of 2972 preantral follicles were histologically examined, i.e. a minimum of 150 follicles per treatment. When data of all treatments were combined, the percentage of normal preantral follicles was 77.6% in control ovarian fragments, 51.7% in fragments that underwent the toxicity test, and 43.6% in fragments that were cryopreserved, respectively.

When compared to control fragments, the percentage of normal preantral follicles (77.6%) was significantly ($P < 0.05$) reduced after exposure of ovarian tissue to cryopreservation in all cryoprotectants used and in both concentrations tested (Table 1). After the toxicity test, no significant ($P > 0.05$) difference among the treatments was observed, when the cryoprotectants were used at 1.5 M. However, at a concentration of 3.0 M, PROH was significantly ($P < 0.05$) more toxic than the three other cryoprotectants, since doubling the concentration of DMSO, EG and GLY did not lead to a further significant ($P > 0.05$) reduction of the percentage of normal preantral follicles. After freezing/thawing, the ovarian fragments cryopreserved in 1.5 M DMSO and EG showed a significantly ($P < 0.05$) higher percentage of normal preantral follicles, while those cryopreserved in 1.5 M GLY had significantly ($P < 0.05$) less normal follicles. In contrast to that of EG, increase of the concentration of DMSO, GLY and PROH to 3 M resulted in a significant ($P < 0.05$) reduction in the percentage of normal preantral follicles. When the percentages of normal preantral follicles in the toxicity test were

compared with those found after cryopreservation, significant ($P < 0.05$) lower values were found when tissues had been frozen/thawed in the presence of PROH or GLY at a concentration of 1.5 and 3 M.

Table 1.

Normal preantral follicles (%) in ovarian fragments that were untreated (controls), in ovarian fragments that were treated with cryoprotectant but not frozen/thawed (toxicity test), and in ovarian fragments that were frozen/thawed in presence of cryoprotectant (cryopreservation) as determined by histological evaluation

Treatment		Cryoprotectant				Controls
		GLY	EG	DMSO	PROH	
Toxicity test	1.5 M	50.7 ^{*,aAC} (77/152)	52 ^{*,aAC} (87/167)	51.6 ^{*,aAC} (81/157)	62.5 ^{*,aAC} (115/184)	77.6 (128/165)
	3.0 M	55.1 ^{*,aAC} (97/176)	56.5 ^{*,aAC} (100/177)	54.4 ^{*,aAC} (98/180)	38.7 ^{*,bBC} (69/178)	
Cryopreservation	1.5 M	24.5 ^{*,cAD} (49/198)	59.6 ^{*,aAC} (106/178)	67.6 ^{*,aAC} (127/188)	44.9 ^{*,bAD} (83/185)	
	3.0 M	13.5 ^{*,dBD} (25/184)	64.5 ^{*,aAC} (98/152)	54.2 ^{*,bBC} (97/179)	27.9 ^{*,cBD} (48/172)	

Values within rows (a, b, c, d) are different ($P < 0.05$); values within columns (A, B) within the same test (toxicity or cryopreservation) are different ($P < 0.05$); values within columns (C, D) within concentrations (1.5 or 3.0 M) are different ($P < 0.05$).

* $P < 0.05$, significantly different from control.

3.2. Percentage of degenerated preantral follicles after toxicity test and cryopreservation

Histological analysis of the ovarian tissue showed that normal (Fig. 1A) and degenerated follicles (Fig. 1B) were found both in control fragments and in fragments that had been used for toxicity test or cryopreservation. Two grades of degeneration were found: grade 1 when the oocyte was damaged, and grade 2 when both oocyte and granulosa cells were degenerated. Table 2 shows the percentages of grade 1 and grade 2 degenerated preantral follicles in control fragments and fragments from the toxicity test and cryopreservation, respectively. A significant ($P < 0.05$) predominance of degenerated grade 1 follicles over those of grade 2 was observed in control fragments. Similar results were obtained in toxicity tests, using the lower concentration of PROH or both concentrations of GLY, EG or DMSO. Furthermore, after cryopreservation, significantly ($P < 0.05$) higher values of degenerated grade 1 follicles was observed in all tests, except when 3.0 M GLY or PROH were used as cryoprotectants. In toxicity tests, the significantly ($P < 0.05$) highest percentage of degenerated grade 2 follicles was observed after exposure of fragments to 3.0 M EG or PROH, while with 1.5 M PROH, 3 M GLY and DMSO also resulted in significantly ($P < 0.05$) higher percentages of such follicles but yet significantly ($P < 0.05$) lower than the former treatments. After cryopreservation, the significantly ($P < 0.05$) highest percentages of grade 2 follicles were found after exposure to 3 M GLY or 3 M PROH.

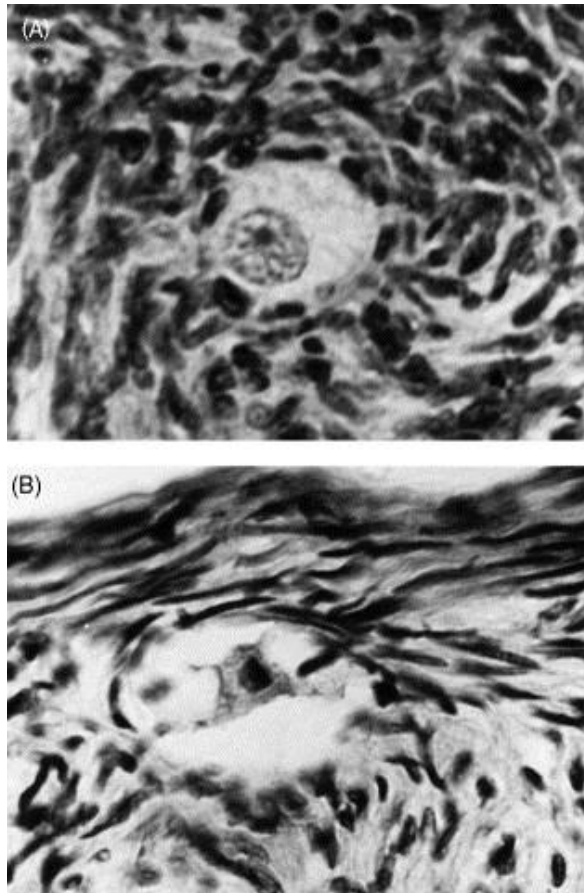


Fig. 1. Preantral follicles in ovarian tissue after histological analysis: (A) normal; (B) degenerated (400×).

Table 2 Degenerating 1 and 2 preantral follicles (%) in ovarian fragments that were untreated (controls), in ovarian fragments that were treated with cryoprotectant but not frozen/thawed (toxicity test), and in ovarian fragments that were frozen/thawed in presence of cryoprotectant (cryopreservation) as determined by histological evaluation

Treatment		Cryoprotectant								Controls	
		GLY		EG		DMSO		PROH		Deg 1	Deg 2
		Deg 1	Deg 2	Deg 1	Deg 2	Deg 1	Deg 2	Deg 1	Deg 2		
Toxicity test	1.5 M	45.8 ^{*ac}	3.5 ^{*,be}	41.6 ^{*ac}	6.4 ^{*,be}	45.3 ^{*ad}	3.1 ^{*,be}	29.8 ^{*ad}	7.7 ^{*,be}	21.5 ^a	0.9 ^b
	3.0 M	35.9 ^{*ac}	9 ^{*,be}	32 ^{*ac}	11.5 ^{*,be}	38.9 ^{*ac}	6.7 ^{*,be}	34.7 ^{*ad}	26.6 ^{*ac}		
Cryopreservation	1.5 M	51.6 ^{*ad}	23.9 ^{*,bf}	35.9 ^{*ac}	4.5 ^{*,be}	27.6 ^{ac}	4.8 ^{*,be}	43.5 ^{*ac}	11.6 ^{*,be}		
	3.0 M	44.4 ^{*ac}	42.1 ^{*af}	22.8 ^{ac}	12.7 ^{*,be}	38.5 ^{*ac}	7.3 ^{*,be}	24.9 ^{ac}	47.2 ^{*,bf}		

Values within rows (a, b) between Deg 1 × Deg 2 are different ($P < 0.05$); values within columns (c, d) within Deg 1 in the same concentration (1.5 × 3.0 M) are different ($P < 0.05$); values within columns (e, f) within Deg 2 in the same concentration (1.5 × 3.0 M) are different ($P < 0.05$). * $P < 0.05$, significantly different from control.

3.3. Ultrastructural analysis of the ovarian tissue

Ultrastructural analysis was performed only for sheep preantral follicles that were considered as normal in semi-thin sections stained with toluidine blue. In 93% of normal preantral follicles in control ovarian fragments (Fig. 2) and in 90% of those frozen in 1.5 M DMSO (Fig. 3), oocytes were observed that have a large, well-delimited nucleus pleiomorphic

large mitochondria, with irregular cristae and continuous mitochondrial membranes, and elongated mitochondria with parallel cristae. These follicles furthermore exhibit highly variable numbers of vesicles spread throughout the ooplasm, a well-developed Golgi complex and both smooth and rough endoplasmic reticulum, either as isolated aggregations or as complex associations with mitochondria and vesicles. Granulosa cells around these oocytes had irregularly-shaped nuclei, with a high nucleus-to-cytoplasm ratio. When the ovarian tissue was frozen in EG at 1.5 and 3.0 M, preantral follicles seemed to be well preserved in semi-thin toluidine blue stained sections. Ultrastructurally, however, 85% of these follicles appeared to have an extremely vacuolated oocyte (Fig. 4A and B). In some cases, fusion of these vacuoles had caused the presence of empty cytoplasmic areas. Occasionally, this alteration was associated with loss of granulosa cell content and, in some cases, with oocyte nuclear shrinkage. Initial signs of damage to mitochondrial membranes and cristae were additionally observed in 80% of the oocytes. Furthermore, 90% of granulosa cells were slightly swollen, with a low density of organelles present in their cytoplasm. Some granulosa cells had disappeared, leaving a vacuolated space (Fig. 4C). The follicles contained a retracted oocyte and substantial irregularity of the follicular, oocyte and nuclear outlines.

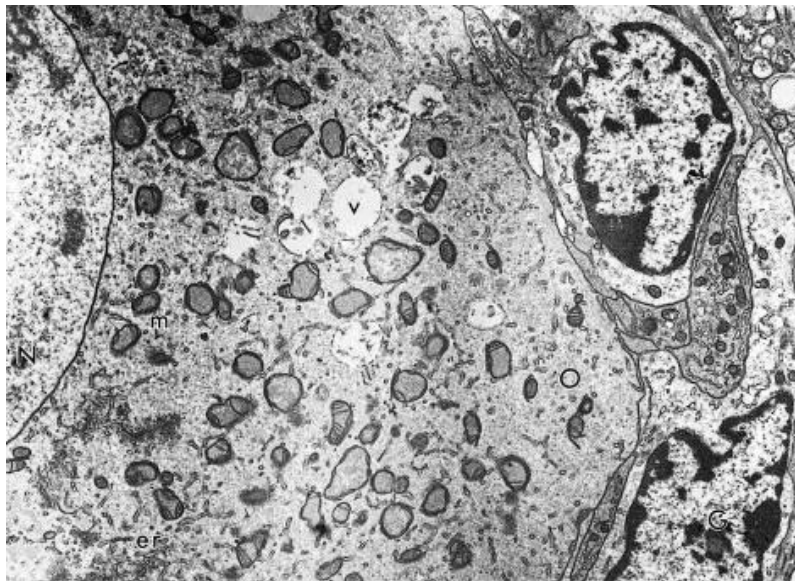


Fig. 2. Normal preantral follicle in control ovarian tissue. O: oocyte; N: nucleus; G: granulosa cell; m: mitochondria; v: vesicles; er: endoplasmic reticulum (4000 \times).

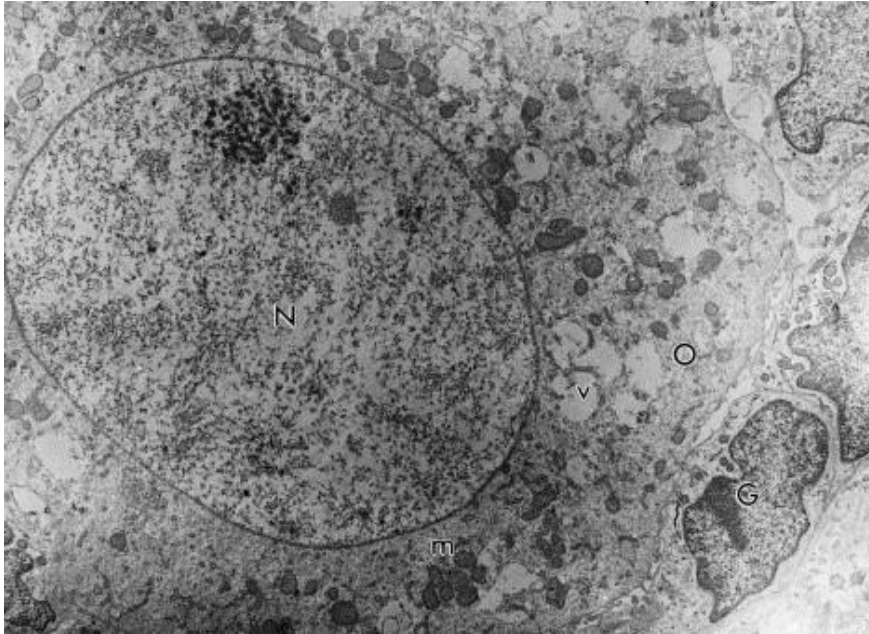


Fig. 3. Preantral follicle in ovarian tissue frozen in 1.5 M DMSO. O: oocyte; N: nucleus; G: granulosa cell; m: mitochondria; v: vesicles (4000 \times).

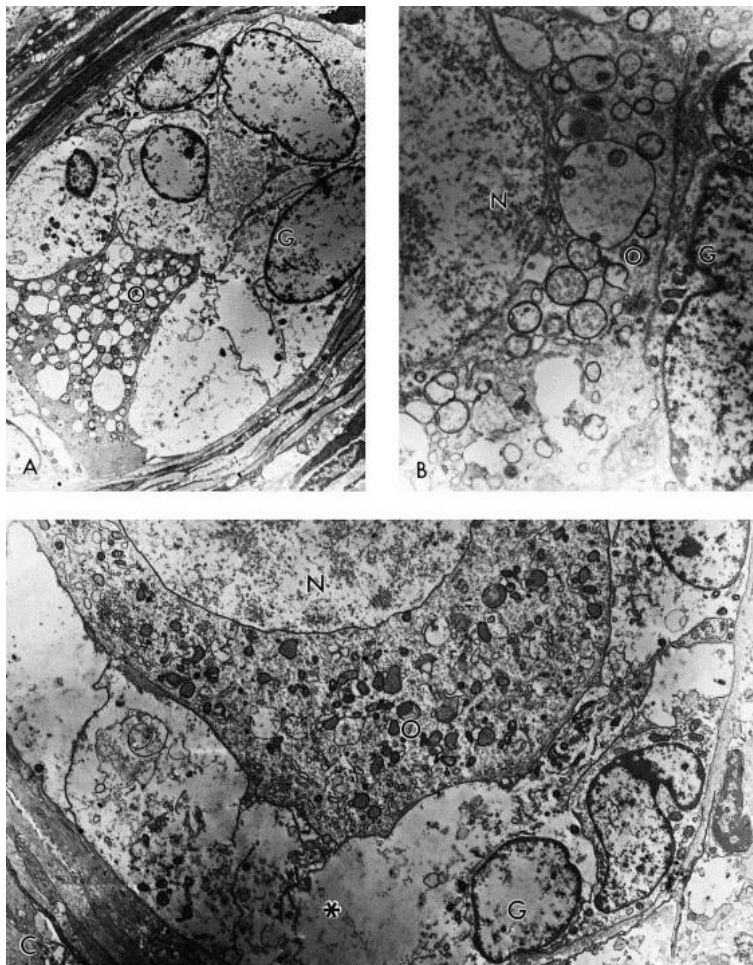


Fig. 4. Preantral follicles in ovarian tissue frozen in EG. O: oocyte; N: nucleus; G: granulosa cell. (A) 1.5 M EG: the oocyte is shrunken and extremely vacuolated. Granulosa cells present loss of cytoplasmic content (2000 \times); (B) 3 M EG: a closer look of the oocyte vacuolization (5500 \times);

(C) 1.5 M EG: observe that some granulosa cells had disappeared, leaving an empty space (asterisk) (2400×).

4. Discussion

The present paper describes a histological and ultrastructural study on toxicity testing and cryopreservation of sheep preantral follicles enclosed in ovarian tissue using GLY, DMSO, PROH and EG as cryoprotectants each at two concentrations, 1.5 and 3.0 M.

Based on the lowered percentage of histologically normal preantral follicles in sheep ovarian fragments, the toxicity test carried out in the present study demonstrated that, at both concentrations tested, GLY, DMSO, and EG, have a comparable damaging (chemical and osmotic) effect. Even with the protecting effect of the cryoprotectant provided, damage can sometimes occur due to osmotic stress or chemical toxicity, especially when cryoprotective agents are used at too high concentrations (Rodrigues et al., 2004b). The damaging effect on follicles appears more pronounced when 3.0 M PROH is used. This confirms a previous finding of Lim et al. (1999), who showed an increased cytotoxic effect of this cryoprotectant on bovine follicles when used in concentrations above 1.5 M. In contrast to our findings, in studies with bovine preantral follicles, Lucci et al. (2004) reported EG to be the most toxic of cryoprotectants evaluated when compared to DMSO and PROH. In this latter study with EG 1.5 M, the percentage of morphologically normal follicles had reduced from 96.9% (control) to 49.2% (toxicity test) and the percentage was maintained without significant difference after cryopreservation (52.5%). Based on these results, the authors concluded that the observed follicular damage was rather by the cryoprotectant than the cryopreservation process itself.

The most dramatic reduction in the percentage of histologically normal preantral follicles was observed after freezing of ovarian tissue fragments in PROH or GLY. The better results were obtained with EG 1.5 and 3.0 M or DMSO 1.5 M, suggesting that these substances maintain the follicular integrity more efficiently after freezing/thawing than the two other cryoprotectants. These findings confirm those of Sommerfeld and Niemann (1999) that different rates of cellular survival after cryopreservation of bovine follicles can be attributed to a variation in the type and

concentration of the cryoprotectants used. Previously, DMSO, EG and PROH have been successfully used to cryopreserve in vitro produced bovine embryos (Bracke and Niemann, 1995). GLY has been widely used for cryopreservation of bovine embryos, because of its low toxicity. It may, however, induce osmotic (Sze'll and Shelton, 1986) and ultrastructural (Lucci et al., 2004) damage in tissues due to its slower permeation. The permeability of GLY is lower than that of PROH, DMSO, and EG (Mazur, 1984 and Fuku et al., 1992). The low permeability of GLY could have caused the lower rate of normal preantral follicles in our sheep ovarian tissues. Also in human ovarian tissue, the permeation of GLY is slower and thus less efficient than PROH and DMSO, while EG exhibits the best permeating action (Hovatta, 2000).

Histological studies facilitate the identification of the primary signs of follicular atresia, like nuclear pycnosis, cytoplasmic damage, detachment of granulosa cells from the oocyte and irregularity of the basement membrane (Jorio et al., 1991, Hulshof et al., 1995 and Demirci et al., 2002). The main degeneration feature observed in the current histological study was nuclear pycnosis in oocytes, i.e. follicular degeneration grade 1. This type of follicular degeneration was also described previously after cryopreservation of ovine (Demirci et al., 2002), bovine (Lucci et al., 2004), caprine (Rodrigues et al., 2004a and Rodrigues et al., 2004b), human (Hovatta et al., 1996) and non-human (Candy et al., 1995) primate ovarian tissues. In vitro studies have shown that the vast majority of cultured preantral follicles of various species have a degenerating or degenerated oocyte, whereas their granulosa cells stay normal and continue to proliferate, which shows that the oocyte is more sensitive to degeneration than the granulosa cells (Erickson, 1986, Figueiredo et al., 1994, Braw-Tal and Yossefi, 1997 and Silva et al., 2001). In contrast, when the ovarian fragments were cryopreserved in 3.0 M PROH, the most common type of degeneration was grade 2 where, in addition to oocyte degeneration, the granulosa cells are disorganized and enlarged in volume (osmotic shock). This type of degeneration occurred to a high degree in toxicity tests using 3 M PROH or 3 M EG. Studying the permeability of cryoprotectant agents in unfertilized eggs, Adams et al. (2003) observed that the temperature of 20 °C is adequate for PROH penetration and that a relative short exposure time is required to minimize toxic effects. Possibly, in our study the

equilibrium period of 20 min was too long to keep follicles intact when 3.0 M PROH was used.

Although histological analysis had shown that after freezing and thawing procedures, the lowest percentages of degenerating sheep follicles were observed with EG or DMSO as cryoprotectants, TEM studies revealed that only preantral follicles cryopreserved with 1.5 M DMSO appeared ultrastructurally normal. Paynter et al. (1999), also found that bovine oocytes cryopreserved in DMSO did not undergo ultrastructural cell damage. In our studies, control and 1.5 M DMSO cryopreserved follicles contained smooth and rough endoplasmic reticulum aggregations, that are either or not in association with mitochondria or vesicles. Such endoplasmic reticulum formations are a common phenomenon commonly occur in fresh sheep preantral follicles (Fair et al., 1997) and other mammals (human: Hertig and Adams, 1967; murine species: Wassarman and Josefowicz, 1978; swine: Tassel and Kennedy, 1980; goat: Silva et al., 2001). Preantral follicles subjected to cryopreservation in EG showed decreased numbers of mitochondria and numerous vesicles in their oocyte that was extremely vacuolated. Similar results were obtained by Matos et al. (2004) after cooling of sheep preantral follicles at 20 °C for about 24 h in TCM 199. Some authors have emphasized that normal sheep oocytes contain a larger number of vacuoles (Cran and Moor, 1980 and Tassel and Kennedy, 1980), but in oocytes showing signs of degeneration, these vacuoles become more numerous (Tassel and Kennedy, 1980). The latter characteristic has generally been considered as an atretic sign in oocytes (Tassel and Kennedy, 1980 and Van Den Hurk et al., 1998), granulosa cells (Hay et al., 1976) and cumulus cells (Assey et al., 1994), and may represent endoplasmic reticulum swelling. Alternatively, these vacuoles may represent altered mitochondria as observed in cryopreserved bovine oocytes by Fuku et al. (1995) and Lucci et al. (2004). Silva et al. (2001) reported that mitochondria with extensive swelling and disappearance of their cristae, as well as endoplasmic reticulum with increased volume, were the first signs of degeneration in goat preantral follicles. TEM studies with cryopreserved bovine (Hyttel et al., 1986 and Fuku et al., 1995) and murine (Schalkoff et al., 1989) oocytes showed that the presence of numerous vesicles led to cellular rupture, possibly due to an increase of the cellular volume caused by osmotic

shock (Asada et al., 2000). Thus, the damage to follicular cell organelles, as visualised at the ultrastructural level, could be the cause of failure in further development of apparently normal cells (Cocero et al., 2002).

5. Conclusion

DMSO is the most suited cryoprotectant in this freezing/thawing procedure, preserving sheep preantral follicles within ovarian tissue, because it may have permeated just quick enough to prevent osmotic shock, and may have low enough chemical toxicity to avoid toxic changes during equilibration period. With further improvement of the cryopreservation protocol, it will be possible to preserve preantral follicles for a long period and to use them, after thawing, for in vitro growth, maturation and fertilization programs or transplantation studies.

Acknowledgements

This work was supported by CNPq. Regiane Rodrigues dos Santos is a recipient of a grant from FUNCAP of Brazil. The authors thank Dr. Edilberto Silveira, PhD (CENAUREMN), Dr. José Ferreira Nunes, PhD (LATSCO), Dr. Vicente José de Figueirêdo Freitas, PhD (LFCR) and AKZO-NOBEL for the logistical support.

References

- Adams, S.L., Kleinhans, F.W., Mladenov, P.V., Hessian, P.A., 2003. Membrane permeability characteristics and osmotic tolerance limits of sea urchin (*Evechinus chloroticus*) eggs. *Cryobiology* 47, 1–13.
- Amorim, C.A., Rondina, D., Rodrigues, A.P.R., Gonçalves, P.B.D., Figueiredo, J.R., 2003a. Cryopreservation of isolated ovine primordial follicles with propylene glycol and glycerol. *Fertil. Steril.* 81, 735–740.
- Amorim, C.A., Rondina, D., Rodrigues, A.P.R., Costa, S.H.F., Gonçalves, P.B.D., Figueiredo, J.R., 2003b. Isolated ovine primordial follicles cryopreserved in different concentrations of ethylene glycol. *Theriogenology* 60, 735–742.
- Asada, M., Horri, M., Mogo, T., Fukui, Y., Ishikawa, H., Ohsumi, S., 2000. In vitro maturation and ultrastructural observation of cryopreserved minke whale (*Balaenoptera acutorostrata*). *Biol. Reprod.* 62, 253–259.

- Assey, R.J., Hyttel, P., Greve, T., Purwantara, B., 1994. Oocyte morphology in dominant and subordinate follicles. *Mol. Reprod. Dev.* 37, 335–344.
- Baird, D.T., Webb, R., Campbell, B.K., Harkness, L.M., Gosden, R.G., 1999. Long-term ovarian function in sheep after ovariectomy and transplantation of autografts stored at -196°C . *Endocrinology* 140, 462–471.
- Bracke, C., Niemann, H., 1995. New aspects in the freezing of embryos from livestock. Proceedings of the 11th Scientific Meeting of European Embryo Transfer Association. Fondation Marcel Merieux, Lyon, France, '101–111.
- Braw-Tal, R., Yossefi, S., 1997. Studies in vivo and in vitro on the initiation of follicle growth in the bovine ovary. *J. Reprod. Fertil.* 109, 165–171.
- Candy, C.J., Wood, M.J., Whittingham, D.G., 1995. Follicular development in cryopreserved marmoset ovarian tissue after transplantation. *Hum. Reprod.* 9, 2334–2338.
- Candy, C.J., Wood, M.J., Whittingham, D.G., 1997. Effect of cryoprotectants on the survival of follicles in frozen mouse ovaries. *J. Reprod. Fertil.* 110, 11–19.
- Carroll, J., Gosden, R.G., 1993. Transplantation of frozen-thawed mouse primordial follicles. *Hum. Reprod.* 8, 1163–1167.
- Cecconi, S., Capacchietti, G., Russo, V., Lli, P.B., Mattioli, M., Barboni, B., 2004. In vitro growth of preantral follicles isolated from cryopreserved ovine ovarian tissue. *Biol. Reprod.* 70, 12–17.
- Cocero, M.J., de la Espina, M.D., Aguilar, B., 2002. Ultrastructural characteristics of fresh and frozen-thawed ovine embryos using two cryoprotectants. *Biol. Reprod.* 66, 1244–1258.
- Cox, S.L., Shaw, J., Jenkin, G., 1996. Transplantation of cryopreserved fetal ovarian tissue to adult recipient in mice. *J. Reprod. Fertil.* 107, 315–322.
- Cran, D.G., Moor, R.M., 1980. The development of oocytes and ovarian follicles of mammals. *Sci. Prog.* 66, 371–383.
- Demirci, B., Salle, B., Frappart, L., Franck, M., Guerin, J.F., Lornage, J., 2002. Morphological alterations and DNA fragmentation in oocytes from primordial and primary follicles after freezing–thawing of ovarian cortex in sheep. *Fertil. Steril.* 77, 595–600.
- Erickson, G.F., 1986. An analysis of follicle development and ovum maturation. *Semin. Reprod. Endocrinol.* 1, 233–254.
- Fair, T., Hulshof, S.C.J., Hyttel, P., Greve, T., Boland, M., 1997. Oocyte ultrastructure in bovine primordial to early tertiary follicles. *Anat. Embryol.* 196, 327–336.
- Figueiredo, J.R., Hulshof, S.C.J., van den Hurk, R., Nusgens, B., Bevers, M.M., Ectors, F.J., Beckers, J.F., 1994. Preservation of oocyte and granulosa cell morphology in bovine preantral follicles cultured in vitro. *Theriogenology* 41, 1333–1346.
- Fuku, E., Kojima, T., Shioya, Y., Marcus, G.J., Downey, B.R., 1992. In vitro fertilization and development of frozen-thawed bovine oocytes. *Cryobiology* 29, 485–492.

- Fuku, E., Xia, L., Downey, B.R., 1995. Ultrastructural changes in bovine oocytes cryopreserved by vitrification. *Cryobiology* 32, 139–156.
- Gunasena, K.T., Villines, P.M., Critser, E.S., Critse, J.K., 1997a. Live births after autologous transplant of cryopreserved mouse ovaries. *Hum. Reprod.* 12, 101–106.
- Gunasena, K.T., Lakey, J.R.T., Villines, P.M., Critser, E.S., Critse, J.K., 1997b. Allogeneic and xenogeneic transplantation of cryopreserved ovarian tissue to athymic mice. *Biol. Reprod.* 57, 226–231.
- Harp, R., Leibach, J., Black, J., Keldahl, C., 1994. Cryopreservation of murine ovarian tissue. *Cryobiology* 31, 336–343.
- Hay, M.F., Cran, D.G., Moor, R.M., 1976. Structural changes occurring during atresia in sheep ovarian follicles. *Cell Tissue Res.* 169, 515–529.
- Hertig, A.T., Adams, E.C., 1967. Studies on the human oocyte and its follicle. I. Ultrastructural and histochemical observation on the primordial follicle stage. *J. Cell Biol.* 34, 647–675.
- Hovatta, O., Silye, R., Krausz, T., Abir, R., Margara, R., Trew, G., 1996. Cryopreservation of human ovarian tissue using dimethylsulphoxide and propanediol–sucrose as cryoprotectant. *Hum. Reprod.* 11, 1268–1272.
- Hovatta, O., 2000. Cryopreservation and culture of human primordial ovarian follicles. *Mol. Cell. Endocrinol.* 169, 95–97.
- Hulshof, S.C.J., Figueiredo, J.R., Beckers, J.F., Bevers, M.M., Van Den Donk, H.A., Van Den Hurk, R., 1995. Effects of fetal bovine serum, FSH and 17-estradiol on the culture of bovine preantral follicles. *Theriogenology* 44, 217–226.
- Hyttel, P., Xu, K.P., Smith, S., Greve, T., 1986. Ultrastructure of in vitro oocyte maturation in cattle. *J. Reprod. Fertil.* 78, 615–625.
- Jorio, A., Mariana, J.C., Lahlou-Kassi, A., 1991. Development of the population of ovarian follicles during their prepubertal period in D'man and Timahdite sheep. *Anim. Reprod. Sci.* 26, 239–250.
- Lim, J.M., Ko, J.J., Hwang, W.S., Chung, H.M., Niwa, K., 1999. Development of in vitro matured bovine oocytes after cryopreservation with different cryoprotectants. *Theriogenology* 51, 1303–1310.
- Lucci, C.M., Kacinskis, M.A., Lopes, L.H.R., Rumpf, R., Bao, S.N., 2004. Effect of different cryoprotectants on the structural preservation of follicles in frozen zebu bovine (*Bos indicus*) ovarian tissue. *Theriogenology* 61, 1101–1114.
- Matos, M.H.T., Andrade, E.R., Lucci, C.M., Bao, S.N., Silva, J.R.V., Santos, R.R., Ferreira, M.A.L., Figueiredo, J.R., 2004. Morphological and ultrastructural analysis of sheep primordial follicles preserved in 0.9% saline solution and TCM 199. *Theriogenology* 62, 65–80.
- Mazur, P., 1984. Freezing of living cells: mechanisms and implications. *Am. Physiol. Soc.*, 125–142.

- Oktay, K., Newton, H., Ausbard, Y., Salha, O., Gosden, R.G., 1998. Cryopreservation of immature human oocytes and ovarian tissue: an emerging thecnology? *Fertil. Steril.* 353, 1–7.
- Paynter, S.J., Cooper, A., Fuller, B., Shaw, R.W., 1999. Cryopreservation of bovine ovarian tissue: structural normality of follicles after thawing and culture in vitro. *Cryobiology* 38, 301–309.
- Rodrigues, A.P.R., Amorim, C.A., Costa, S.H.F., Matos, M.H.T., Santos, R.R., Lucci, C.M., Bao, S.N., Figueiredo, J.R., 2004a. Cryopreservation of caprine ovarian tissue using glycerol and ethylene glycol. *Theriogenology* 61, 1009–1024.
- Rodrigues, A.P.R., Amorim, C.A., Costa, S.H.F., Matos, M.H.T., Santos, R.R., Lucci, C.M., Bao, S.N., Ohashi, O.M., Figueiredo, J.R., 2004b. Cryopreservation of caprine ovarian tissue using dimethylsulphoxide and propanediol. *Ani. Reprod. Sci.* 84, 211–227.
- Salle, B., Lornage, J., Demirci, B., Vaudoyer, F., Poirel, M.T., Frank, M., Rudigoz, R.C., Guerin, J.F., 1999. Restoration of ovarian steroid secretion and histologic assessment after freezing, thawing, and autograft of a hemi-ovary in sheep. *Fertil. Steril.* 72, 366–370.
- Schalkoff, M.E., Oskowitz, S.P., Powers, R.D., 1989. Ultrastructural observations of human and mouse oocytes treated with cryopreservatives. *Biol. Reprod.* 40, 379–393.
- Shaw, J.M., Oranratnachai, A., Trounson, A.O., 2000. Fundamental cryobiology of mammalian oocytes and ovarian tissue. *Theriogenology* 53, 59–72.
- Silva, J.R.V., Bao, S.N., Lucci, C.M., Carvalho, F.C.A., Andrade, E.R., Ferreira, M.A.L., Figueiredo, J.R., 2001. Morphological and ultrastructural changes occurring during degeneration of goat preantral follicles preserved in vitro. *Anim. Reprod. Sci.* 66, 209–223.
- Sommerfeld, V., Niemann, H., 1999. Cryopreservation of bovine in vitro produced embryos using ethylene glycol in controlled freezing or vitrification. *Cryobiology* 38, 95–105.
- Sze'Il, A., Shelton, J.N., 1986. Role of equilibration before rapid freezing of mouse embryos. *J. Reprod. Fertil.* 78, 699–703.
- Tassel, R., Kennedy, J.P., 1980. Early follicular development and atretic changes in ovary of the lamb: fine structure and histochemistry. *Aust. J. Biol. Sci.* 33, 675–687.
- Van Den Hurk, R., Spek, E.R., Hage, W.J., Fair, T., Ralph, J.H., Schotanus, K., 1998. Ultrastructure and viability of isolated bovine preantral follicles. *Hum. Reprod.* 4, 833–841.
- Wassarman, P.M., Josefowicz, W.J., 1978. Oocyte development in the mouse: an ultrastructural comparison of oocytes isolated at various stage of growth and meiotic competence. *J. Morphol.* 156, 209–235.